

## Early detection of pneumonia by $^{19}\text{F}$ MRI

U. Flögel<sup>1</sup>, B. Ebner<sup>2</sup>, P. Behm<sup>2</sup>, and J. Schrader<sup>2</sup>

<sup>1</sup>Institut für Herz- und Kreislaufphysiologie, Heinrich-Heine-Universität Düsseldorf, Düsseldorf, NRW, Germany, <sup>2</sup>Institut für Herz- und Kreislaufphysiologie, Heinrich-Heine-Universität Düsseldorf

### Introduction

For noninvasive visualization of inflammatory processes by MRI up to now predominantly superparamagnetic iron oxide particles (SPIOs) are used, taking advantage of the high affinity of these species for the monocyte-macrophage system<sup>[1,2]</sup>. Since SPIOs lead to a depletion of the MR signal, this approach cannot be applied to the lung, because the anatomical structure of the lung is such that already under control conditions  $^1\text{H}$  MR images appear dark. In the present study we examined the feasibility to image pulmonary inflammation with a positive  $^{19}\text{F}$  contrast. For this purpose we used emulsified perfluorocarbons (PFCs) as contrast agent, which are biochemically inert and are phagocytized similar to SPIOs by the reticuloendothelial system<sup>[3,4]</sup>.

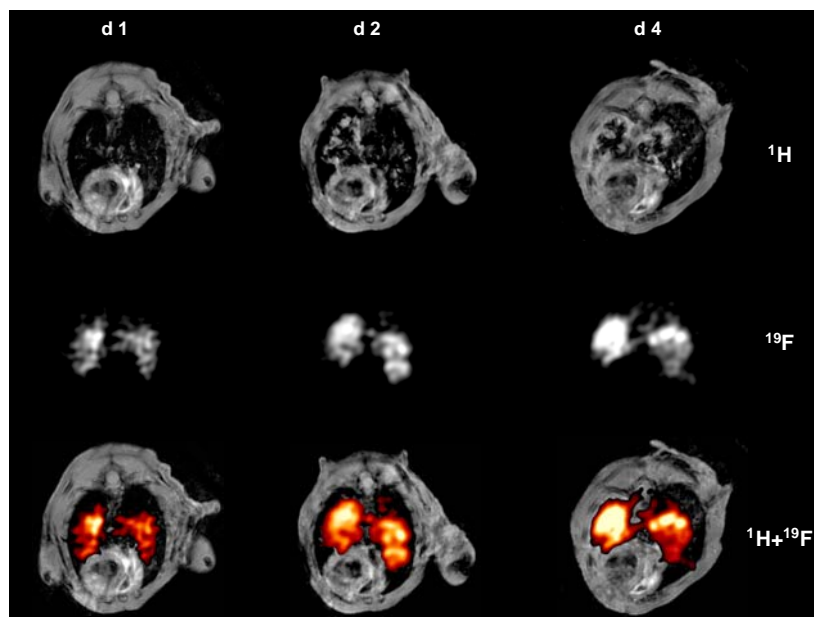
### Methods

Experiments were performed at a vertical Bruker DRX Wide Bore NMR spectrometer operating at frequencies of 400.13 MHz for  $^1\text{H}$  and 376.46 MHz for  $^{19}\text{F}$  measurements using a Bruker Microimaging unit (Mini 0.5) equipped with an actively shielded 57-mm gradient set (200 mT/m maximum gradient strength, 110  $\mu\text{s}$  rise time at 100% gradient switching) and a  $^1\text{H}/^{19}\text{F}$  30-mm birdcage resonator. For induction of acute pneumonia mice were exposed to aerosolized lipopolysaccharide (LPS) in a custom-built cylindrical chamber connected to an air nebulizer (MicroAir; Omron Healthcare). LPS from *Salmonella enteritidis* (Sigma-Aldrich) was dissolved in 0.9% saline (100-500  $\mu\text{g}/\text{ml}$ ), and mice were allowed to inhale LPS for 30 min. After exposure to LPS, 200-500  $\mu\text{l}$  of a perfluoro crown ether (15C5) emulsion (10%, particle size 130 nm) was injected into the tail vein of the mice. In order to monitor the time course of PFC accumulation within the thorax, anatomically corresponding  $^1\text{H}$  and  $^{19}\text{F}$  MR images were acquired with the following parameters: FOV 3x3  $\text{cm}^2$ ,  $^1\text{H}$ : Respiratory-triggered FLASH, slice thickness 1 mm, matrix 256x256, acquisition time 1 min,  $^{19}\text{F}$ : RARE (RARE factor 64), slice thickness 2 mm, matrix 128x128, acquisition time 20 min.

### Results and Discussion

One day after induction of pneumonia neither  $^1\text{H}$  gradient nor  $^1\text{H}$  spin echo images gave evidence for the presence of lung injury. However, at the same point in time  $^{19}\text{F}$  images unequivocally showed PFC infiltration into both pulmonary lobes (Fig. 1, 1<sup>st</sup> column). Follow-up imaging after 2 and 4 days revealed alterations in  $^1\text{H}$  images at the same location as the early  $^{19}\text{F}$  signals (Fig. 1, 2<sup>nd</sup> and 3<sup>rd</sup> column). The occurrence of these  $^1\text{H}$  signals within the lung is most likely caused by the development of edema with progressive pneumonia, which could be predicted by  $^{19}\text{F}$  MRI after PFC administration. Histology confirmed the presence of infiltrating monocytes/macrophages already at day 1 after LPS exposition. Additional experiments with stepwise increasing dosage of LPS indicated that severity of pneumonia is reflected by the intensity of the PFC signal (integral) determined in  $^{19}\text{F}$  images.

The results of the present study show that intravenous application of emulsified PFCs after induction of pneumonia results in the accumulation of these particles in affected lung areas, most likely after phagocytosis by the monocyte-macrophage system. In summary, PFCs can serve as positive contrast agent for pulmonary inflammation, which is characterized by a high degree of specificity due to the lack of any  $^{19}\text{F}$  background. Since PFCs are not toxic, this approach may also be suitable for human applications.



**Fig. 1:**  $^1\text{H}$  (top) and  $^{19}\text{F}$  (middle) MR images of the mouse thorax 1, 2, and 4 days after 30 min of exposition to aerosolized LPS. For merging of data sets the hot iron colour lookup table was applied to  $^{19}\text{F}$  images.

### References

- [1] Kleinschnitz C et al., *J Cereb Blood Flow Metab* 23: 1356-1361 (2003).
- [2] Beckmann N et al., *Radiology* 240: 717-724 (2006).
- [3] Mattrey RF et al., *Radiology* 145: 755-758 (1982).
- [4] Flögel U et al., *Circulation* 118: 140-148 (2008).