

# Longitudinal In Vivo Evaluation of Articular Cartilage Injuries in Small Animals Using Quantitative MR Imaging

C. Taylor<sup>1</sup>, R. Doan<sup>1,2</sup>, A. Dang<sup>3</sup>, S. Majumdar<sup>1</sup>, and C. Ma<sup>3</sup>

<sup>1</sup>Radiology, University of California, San Francisco, San Francisco, CA, United States, <sup>2</sup>Cleveland Clinic Lerner College of Medicine, Cleveland, OH, United States, <sup>3</sup>Orthopedics, University of California, San Francisco, San Francisco, CA, United States

## INTRODUCTION

In osteoarthritis (OA), high field MRI allows a quantitative measure of volumetric and biochemical changes of cartilage. Human studies have shown that  $T_{1\rho}$  and  $T_2$  mapping techniques have the ability to provide highly accurate and quantitative measurements[1] of articular cartilage degeneration *in vivo*. However, the development of pharmaceuticals to treat OA rests on the characterization of disease states in small animals, and this characterization is best done longitudinally to avoid confounding factors such as individual variation. Towards this end, we have characterized the rabbit anterior cruciate ligament (ACL) transection model of OA longitudinally *in vivo* over 12 weeks using  $T_{1\rho}$  and  $T_2$  mapping techniques, and we have used this model to assess the effects of the common antibiotic doxycycline[2] on OA progression.

## METHODS

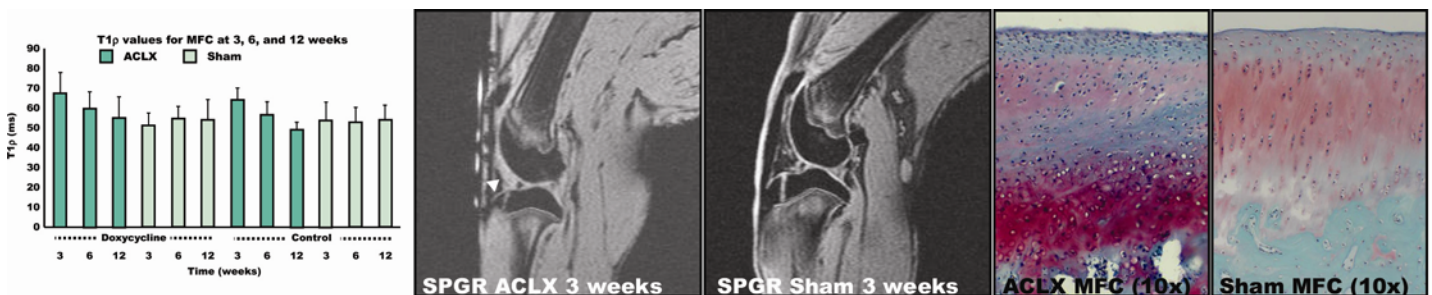
12 female New Zealand White (NZW) rabbits underwent bilateral knee surgery. On the left (ACLX), a medial arthrotomy was performed and the ACL was transected; on the right, only a medial arthrotomy was performed. Following surgery, the treatment group received 2.2 mg/kg doxycycline (MED4VETS, Sandy, UT) orally twice per day for the duration of the study. Control animals received no treatment. MRI data were acquired 3, 6, and 12 weeks post surgery on a 3T GE Excite Signa system using a quadrature transmit/receive knee coil. The protocol included 3 sequences: sagittal three-dimensional water excitation high-resolution spoiled gradient-recalled (SPGR) imaging (TR/TE = 15/6.7 ms, flip angle = 12, FOV = 12 cm, matrix = 512 x 256, slice thickness = 1 mm, bandwidth = 31.25 kHz, number of excitation [NEX] = 1); a sagittal 3D  $T_{1\rho}$ -weighted imaging sequence developed previously in our lab[3] (TR/TE = 9.3/3.7 ms; FOV = 14 cm, matrix = 256 x 128, slice thickness = 1 mm, BW = 31.25 kHz, VPS = 64,  $T_{rec}$  = 1.5 s, TSL = 0, 10, 40, 80 ms,  $F_{SL}$  = 500 Hz); and a  $T_2$  quantification sequence (TE = 4.1, 14.5, 25, 45.9 ms) based on  $T_2$  preparation pulses containing an MLEV train of nonselective composite  $90_x180_y90_x$  refocusing pulses. Cartilage was segmented using SPGR images into lateral femoral condyle (LFC), medial femoral condyle (MFC), lateral tibia (LT), medial tibia (MT), and patellofemoral (PF) compartments. Mean values from each image slice for  $T_{1\rho}$  and  $T_2$  were calculated, and results were analyzed using a two-way analysis of variance (ANOVA) with repeated measures on one factor. After sacrifice, harvested cartilage was stained with hematoxylin, safranin O, and fast green; histology images were obtained with an Olympus CX41 microscope and a Nikon Coolpix 500 camera.

## RESULTS

Average  $T_{1\rho}$  and  $T_2$  values for the ACLX knees were higher than the corresponding values for the contralateral sham operated knees following surgery (MFC data shown). A significant effect ( $p < 0.05$ ) for time was found for  $T_{1\rho}$  data in the MFC, LFC, and MT compartments of the ACLX knee; significant differences from the 3 week group were also found in the MFC (6,12 wk), LFC (12 wk), and MT (6, 12 wk). No significant effects were demonstrated in the  $T_{1\rho}$  data for the sham-operated knee. Similar effects were found for  $T_2$  data, with the addition of significant effects for time (right LT) and for 3 and 12 week differences (right LFC). A significant interaction between time and doxycycline treatment was found in the  $T_2$  data for only the LT; no significant interactions were found in any compartment for  $T_{1\rho}$ . Histology demonstrates hypercellularity and disorganization suggestive of fibrocartilage formation in ACLX knees compared to sham. SPGR data is indicative of synovitis (arrow) at 3 weeks in the ACLX knees, which tends to resolve by 12 weeks (not shown), and is present to a much lesser degree in the sham-operated knees.

## DISCUSSION

We have demonstrated the ability of MRI to follow the changes induced by ACL transection in rabbit articular cartilage longitudinally and *in vivo*: early elevation of  $T_{1\rho}$  and  $T_2$  values in ACLX knees suggestive of early cartilage matrix destruction[3] and subsequent decrease suggesting replacement of hyaline cartilage with fibrocartilage were noted. In addition, morphologic MR and histological data suggests a mechanism of inflammation and repair following ACL transection surgery. Together, this demonstrates the ability to make longitudinal measurements and compare disease states of small animals as they evolve over time. Although the effects of doxycycline were not significant in this study, the methodology presented here will provide a solid framework for future therapeutic studies.



## ACKNOWLEDGEMENTS

This work was supported by grant A108301 from the American Orthopedics Society for Sports Medicine.

## REFERENCES

1. Li, X., et al., Osteoarthritis Cartilage, 2007. 15(7): p. 789-97.
2. Brandt, K.D., J Rheumatol Suppl, 1995. 43: p. 149-51.
3. Li, X., et al. Magn Reson Med, 2008. 59(2): p. 298-307.