

On the Amenability of Ghost Imaging to Large Parallel Acceleration Factors

I. Koktzoglou¹, and R. R. Edelman¹

¹Department of Radiology, NorthShore University HealthSystem, Evanston, IL, United States

Introduction

Ghost imaging is a newly proposed methodology for magnetic resonance angiography (MRA) that eliminates the need for image subtraction. Using a 3D pulse sequence that acquires slices outside of the body, the method works by modulating arterial signal to produce ghost artifacts. Arterial ghost artifacts localizing in air outside of the body are then processed and viewed along multiple orientations as is possible with conventional MRA.

Given the sparsity of the arterial ghost artifacts located outside of the body and the complete absence of background signal, Ghost imaging may support increased levels of parallel acceleration. We tested the hypothesis that Ghost MRA may enable higher acceleration factors than conventional, subtraction-based MRA.

Subjects and Methods

The thighs of 7 volunteers (ages 18-33) were imaged on a 32-channel 1.5 T scanner (Avanto, Siemens Medical, Erlangen) equipped with multi-element peripheral vascular and body coils. Unenhanced angiography using parallel (GRAPPA) acceleration factors (AF) of 4-8 was performed using 3D ECG-triggered partial-Fourier turbo spin-echo pulse sequences. Imaging of one subject with an AF of 11 was also attempted. Conventional, subtractive unenhanced MRA was performed by subtracting an image set acquired during systole from one acquired during diastole (1). Unenhanced Ghost MRA was performed by acquiring even k_z lines during diastole and odd k_z lines during systole. Imaging parameters were matched for both methods: TR/TE/flip = 2 cardiac cycles/90 ms/90°, field of view of 35 cm x 50 cm, matrix of 224 x 320, slice thickness of 8 mm, 112 slices (ghost MRA) and 56 slices (subtractive MRA), and scan time of 84 cardiac cycles. Scans were acquired twice for the purposes of estimating image noise. Arterial-to-background relative contrast and contrast-to-noise ratio were computed using region of interest measurements. Statistical comparison of techniques was performed using Wilcoxon signed-rank tests.

Results

Figure 1 shows representative images acquired with the Ghost MRA and subtractive MRA techniques using AF ranging from 4 to 8. Image quality using Ghost MRA was superior for all tested AF. The Ghost MRA method was found to provide better depiction of primary and branch vessels than conventional, subtractive MRA for all acceleration factors investigated, and demonstrated only mild artifact and reduction of vascular detail at very high AF of 8 or 11. Figure 2 shows the contrast-to-noise ratio (CNR) and relative contrast values for both methods. Relative contrast and CNR were significantly larger with Ghost MRA than with conventional, subtraction-based MRA ($P < 0.001$ for both measures).

Conclusions

On the basis of arterial-background contrast, contrast-to-noise ratio, and image quality, Ghost MRA was found to enable much higher parallel acceleration factors than conventional, subtractive MRA. Presumably, the sparsity of image data outside of the body reduces fold-over in the undersampled Ghost images, and thereby reduces image noise related to the g-factor (2). Potential benefits of the high AF Ghost technique for unenhanced and contrast-enhanced Ghost MRA include drastically shortened echo train lengths and highly accelerated steady-state acquisitions.

References: (1) Miyazaki M et al. JMRI 2000;12:776-783. (2) Blaimer et al. ISMRM 2007 #749.

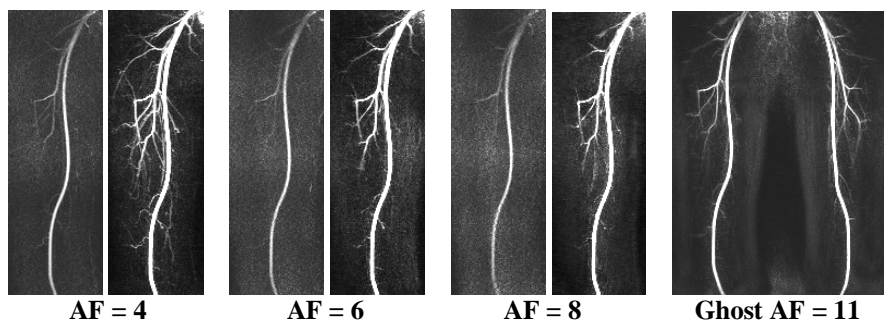


Figure 1. Comparison of maximum intensity projection images of the thighs acquired with conventional subtraction-based MRA (left) and Ghost MRA (right) using AFs of 4-8, as well as Ghost MRA using AF=11. Images were windowed to show parallel imaging artifacts. Note the improved image quality with Ghost MRA for the entire range of acceleration factors.

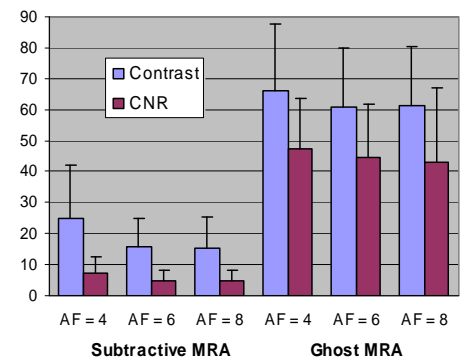


Figure 2. Arterial-to-background relative contrast and CNR values for subtractive MRA and for Ghost MRA. Ghost MRA provided larger contrast and CNR values than conventional subtractive MRA ($P < 0.001$).