

Quantification of Calcifications in Endarterectomy Samples by Means of High-resolution Ultra-short TE Imaging

S. Sharma¹, A. Bornstedt¹, S. Boujraf¹, and V. Rasche¹

¹Internal Medicine II, University Ulm, Ulm, Germany

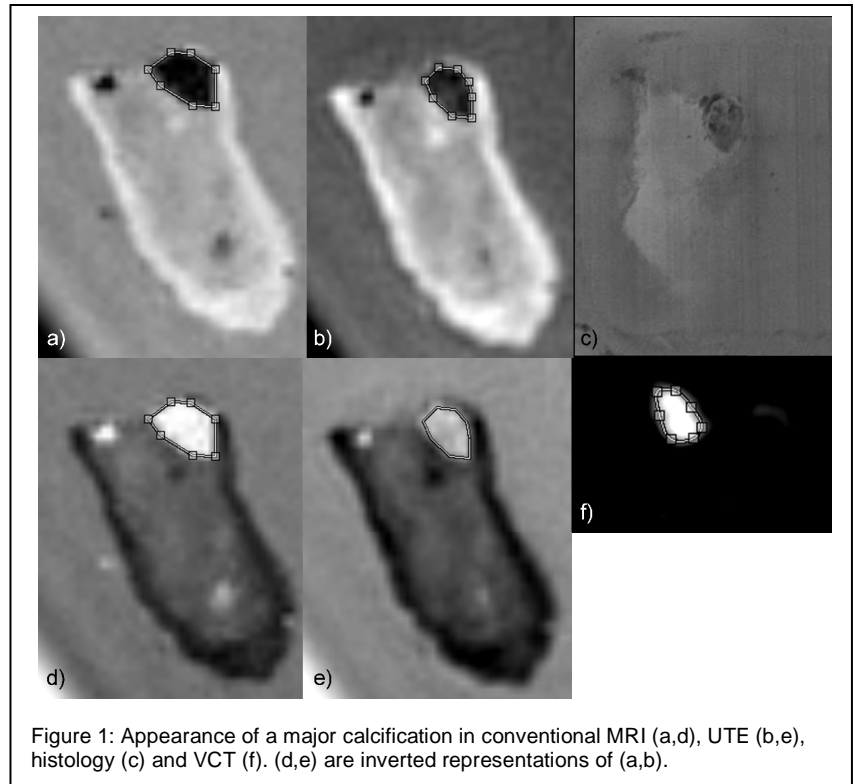
Introduction

Major limitations in plaque characterization rise from calcifications, which are normally identified as simple signal voids in the final image and can often be missed when located in the proximity of low signal regions such as the endoluminal wall. Furthermore, due to susceptibility effects, the volume of calcifications is often overestimated by conventional acquisition techniques. Ultra-short TE imaging (UTE) has been shown to be capable of avoiding complete signal cancellation in calcified regions (1,2) and reveals similar calcification structures when compared to CT. In this contribution, the possible improvement in quantification of the volume of the calcification by means of UTE is assessed in endarterectomy samples and compared to high-resolution volume CT and histology.

Methods

15 endarterectomy samples were preserved in 10% formaldehyde directly after resection. All samples underwent the following MR protocol: T1-weighted (T1W) gradient echo (TE/TR = 5.7/15ms; 0.25³mm³ spatial resolution, fov = 80³mm³, scan duration 2h43m), UTE acquisition TE/TR = 0.05/15ms; 0.25³mm³ spatial resolution, fov = 80³mm³, scan duration 6h33m). All data was acquired on a 3T whole-body system (Achieva, Philips Medical Systems, Best, The Netherlands). After MRI data acquisition, the samples underwent high-resolution volume CT (VCT) on an interventional X-ray system (Allura FD, Philips Medical Systems, The Netherlands). Reconstructions were performed at 0.2³mm³. During imaging, the samples were embedded in agarose gel. After imaging, the samples underwent histological analysis including calcium staining.

For data analysis, the contours of areas of major calcifications were drawn manually in the different data sets and the appearing size of the calcified section was compared amongst the different imaging approaches.



Results

As exemplarily shown in Fig.1, the calcified lesions appear significantly enlarged in the T1W MRI approach (a,d). In direct comparison to the UTE outcomes (b,e) an overestimation of the calcification in the order of 40% was observed. The appearance of the calcification in the UTE images correlates well with histology (c) as well as with the VCT (f) scan. In the UTE image (b) the different densities of calcium, can be nicely appreciated, whereas in the respective T1W image (a), the entire calcified area appears homogeneously black. In cases of histologically proven micro calcifications, complete signal voids in the entire regions were observed in the T1W images. These signal voids could be avoided by applying the UTE technique. The respective samples did not show significant enhancement in the VCT images.

Discussion

This work demonstrates the applicability of high-resolution ultra-short TE MRI for quantification of the volume of calcification. The direct comparison of UTE to conventional gradient echo techniques reveals a significant overestimation of the calcium volume by the conventional techniques. The good agreement of the UTE images with the VCT images and histology implies a similar performance of this technique as the gold-standard CT. Therefore UTE may contribute to a more precise assessment of the plaque structure and facilitate a better prediction of plaque stability.

References: [1] Nielles-Vallespin S et al. Proc ISMRM 2007:440 [2] Herzka DA et al. Proc ISMRM 2008:962