

## **Diffusion Weighted Imaging of the Human Brain in *P. falciparum* Malaria**

C. L. Tosti<sup>1</sup>, J. Muraskin<sup>1</sup>, X. Golay<sup>2</sup>, J. Laothamatas<sup>3</sup>, M. Van Cauteren<sup>4</sup>, M. B. Ooi<sup>1</sup>, V. Lekprasert<sup>3</sup>, N. Tangpukdee<sup>3</sup>, S. Krudsood<sup>3</sup>, W. Leowattana<sup>3</sup>, S. Looareesuwan<sup>3</sup>, P. Wilairatana<sup>3</sup>, R. L. DeLaPaz<sup>1</sup>, G. M. Brittenham<sup>1</sup>, A. M. Brickman<sup>1</sup>, and T. R. Brown<sup>1</sup>

<sup>1</sup>Columbia University, New York, NY, United States, <sup>2</sup>University College London, London, United Kingdom, <sup>3</sup>Mahidol University, Bangkok, Thailand, <sup>4</sup>Philips Healthcare Systems Asia Pacific, Tokyo, Japan

### **Introduction**

With an estimated 1-2 million deaths from malaria each year and recently reported resistance to the latest generation of anti-malarial drugs, a better understanding of the pathogenesis of malaria is imperative (1, 2). *P. falciparum* malaria remains entirely within the vascular space of the brain, and the means whereby it can cause severe neurological dysfunction, coma and death are unknown. To assess the sensitivity of MR to cerebral changes in malaria and, in particular, changes in the apparent diffusion coefficient (ADC), we performed serial MRI studies at 3T in adult patients admitted for malarial treatment in Bangkok, Thailand and compared the results to controls using a voxelwise analysis.

### **Materials and Methods**

We examined 10 adult patients diagnosed with acute uncomplicated falciparum malaria, and 10 adult healthy controls. MRI examinations were performed approximately 24 hours after admission by which time the patients were afebrile (37.8 +/- 0.6 C), and had been administered artemisinin combination therapy and rehydration fluids. The MRI exam was repeated 28 days later after successful antimalarial therapy. All exams were performed in a Philips Achieva 3T MR scanner (Philips Healthcare Systems, Best, The Netherlands) with an 8 channel parallel imaging head coil. The patients and controls were examined with standard radiological scans as well as an identical whole-brain axial diffusion weighted echo planar imaging (DW-EPI) sequence [matrix = 112 x 87; FOV = 240 x 150; 23 slices; slice thickness = 6mm; TR = 2655ms; TE = 88ms, b=1,000]. A 3D magnetization prepared rapid acquisition by gradient echo (MPRAGE) [matrix 192 x 192; FOV = 240 x 150; 60 slices; slice thickness = 2.5mm; TR = 8.4ms; TE = 3.2ms; FA = 8; Turbo Factor = 192] scan was collected for structural information.

### **Data Analysis**

DTIStudio (Johns Hopkins University, Baltimore, MD) was used to create ADC maps from DWI data. MPRAGE images were used to co-register the initial and follow-up ADC maps allowing for a pairwise comparison of the data in the native space of each patient. Additionally, the patients and controls were brought into a normalized group space in order to compare the population of controls to the malaria patients. The processing of the data was performed using Statistical Parametric Mapping V5 (Wellcome Trust, London, UK) and Matlab 7.4 (The Math Works, Natick, MA).

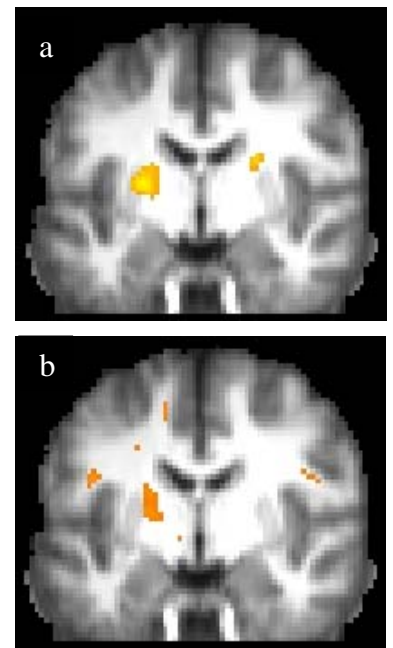
### **Results**

A pairwise t-test comparison between day 1 and day 28 in individual patients showed significant regions of elevated ADC (~5%) during infection (day 1) using a critical t-score of 4.3 (p<0.001) and an extent threshold of 10 voxels (Fig. 1a). Similar results were observed in a comparison of the patient exams on day 1 to the control group of 10 healthy age-matched adults using a t-score of 3.6 (p<0.001; Fig 1b). Comparison of the patient exams on day 28 with the control group showed no regions of significantly elevated ADC using the same selection criteria. Review of the standard T2W and FLAIR radiological exams showed no abnormal signal in the patient studies.

### **Discussion and Conclusion**

We conclude that water diffusivity is increased in white matter, predominantly in the posterior limbs of the internal capsule and the genu of the corpus callosum before successful treatment of patients with acute uncomplicated falciparum malaria. The patients were free of confounding conditions such as fever, dehydration, or vital organ failure. Increased diffusivity in the white matter could be the result of extravascular micro-edema that is not apparent in the standard clinical images. Elevated ADC would result if the function of the blood brain barrier (BBB) was disrupted indirectly by an inflammatory process or directly by the influence of parasitized erythrocytes on the endothelial cells. Combinations of clinical and postmortem investigations in patients, studies in animal models, and research in cell culture have provided evidence for malarial parasite-induced alterations in BBB function in *severe* malaria (3, 4, 5). Our results suggest that MR diffusion at 3T may be sensitive to these neuropathological changes even in *uncomplicated* falciparum malaria.

**References:** 1 Summer AP et al., Semin. Pediatr. Infect. Dis., 16:105-115, (2005). 2 Wongsrichanalai C, et al., Emerg Infect Dis., May; 14(5):716-9, (2008). 3 Medana IM et al., Int J Parasitol., 36:555-568, (2006). 4 Tripathi AK, et al., J Infect Dis. 195:942-50, (2007). 5 Hunt NH, et al., Int J Parasitol. 36:569-582, (2006).



**Fig 1.** Statistical parametric maps showing regions of elevated white matter ADC in malaria patients on day 1 from (a) a pairwise comparison of the exams of the 10 individual patients on day 1 to day 28, and (b) a comparison of the 10 patients exams on day 1 to 10 controls. The underlying image is the composite MPRAGE for the group.