

Quantitative mapping of diffusion characteristics under the cortical surface

B-B. Koo¹, V. Sachdev¹, J. Lee², and D-S. Kim¹

¹Biomedical imaging center, Boston University, Boston, MA, United States, ²Biomedical Engineering, Hanyang University, Seoul, Korea, Republic of

Purpose

Speculating the human brain in terms of structure and function is a challenging issue for current imaging technologies. One of the most important issues is how to avoid ambiguities resulting from limited spatial resolution of current imaging techniques and extract the core information for analysis. Here, we propose a new multi-modal imaging based mapping scheme which may allow robust localized analysis of white matter (WM) diffusivity in peripheral cortex. We expect that this technique may provide a potentiality to extend our focus on more complex structures and their relationships to functions.

Background

Regional specificity of peripheral WM maturation in relation to different grey matter (GM) regions which may imply specific cognitive functions were initially demonstrated by Paul Flechsig [1901]. Maturation of WM continues until the end of the third decade of life. The long-lasting development of the white matter is paralleled by the development of cognitive functions. Considering the efficiency of diffusion tensor imaging (DTI) on white matter region, we may expect that the regional specific characteristics on peripheral WM structure can be detected from DTI with proper mapping technique.

Materials and Methods

T1-weighted (1mm iso-cubic resolution) and DTI data (2mm iso-cubic resolution) from 15 subjects (age: 22-34; male; 3T Philips Intera system) were scanned in the same session with the same FOV to provide a more relevant co-registration process. Peripheral mapping was performed as follows: **step 1**) Affine and nonlinear transformation parameter estimation was performed between the high-resolution anatomical image and the non-diffusion weighted image; **step 2**) Cortical surfaces were automatically extracted from each high-resolution anatomical scan using the Constrained Laplacian-based Automated Segmentation with Proximities (CLASP) algorithm [Kim et al., 2005]; **step 3**) Based on the estimated transformation parameter, reconstructed cortical surface was inversely transformed to DTI space; **step 4**) Using GM/WM matter surface, a Laplacian map was constructed for estimating smooth surface normal vector field; the algorithm searches the closest peripheral WM voxel in DTI parameter image without GM partial volume effect; **step 5**) Diffusion information, including fractional anisotropy (FA), mean diffusivity (MD) and perpendicular diffusion were directly mapped to surface points; **step 6**) Using the fine-surface registration technique [Lyttelton et al., 2007], each subject's surface information was mapped to an average surface template for group analysis. The following two pragmatic issues have been addressed in the present study: (1) reliability analysis of the local vertex-wise mapped sample distribution of derived DTI parameters (FA, MD) with regard to normal distribution assumptions and coefficient of variation (CoV: 100- standard deviation/mean); (2) Analyzing regional pattern, specificity and consistency.

Results

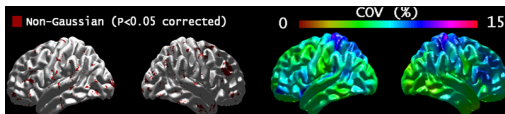


Figure 1: Testing the Gaussianity of group mapped FA values from our proposed surface based method were shown in left side and its coefficient of variation map is shown in right.

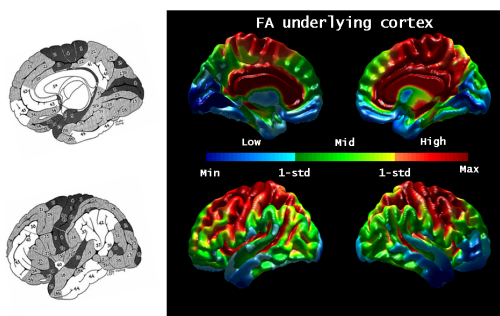


Figure 2: Comparison of group average FA (right) and PF map (left illustration adopted from Flechsig [1]). Color range is divided into three classes based on one standard deviation. Divided pattern of average FA shows significant matching with PF map.

Reliability analysis: while most of region showed gaussian distribution, the percentage of vertices found to be non-Gaussian in the dataset was 5.7 (figure 1 left). CoV of FA values across subjects are shown in right part of figure 3.5. Calculated CoV is generally between 4% and 8.5% (figure 1 right). High CoV were found in superior parietal lobe.

Regional specificity: Figure 2 and 3 shows the spatial FA variation among the different cortical regions. Maximum FA values were located in the motor area which had known to be initially myelinated region (see figure 2 left) in the human cortex. The pattern of FA undergoes dramatic decrease in the inferior part of the cortex. Minimum was observed in inferior temporal and prefrontal region. Overall pattern of FA map with 3 different color classes based on 1-standard deviation showed consistent pattern with PF map: (1) early myelinating primitive zone; (2) a field bordering the primitive zone that myelinates next; (3) a late-myelinating zone, which called "association".

Discussions and Conclusions

Our proposed fully automated multimodal-based mapping approach allows robust definition of peripheral WM structure covering the whole cortical region. Using this technique, we found selective differences in diffusion indices of the WM. FA mapping of the peripheral WM reflects low structural complexity in early myelinated region and high complexity in the region known as late maturation. Also, statistical analysis reveals the regional specificity across the ROIs. This

observation suggests organization of regions by WM density consistent with inherent adaptive brain functions. While most DTI studies have been restricted to several major fiber bundles or some specific region of interests (ROIs), our proposed framework may extend the scope for DTI analysis and improve the diagnostic ability for various neurological disorder.

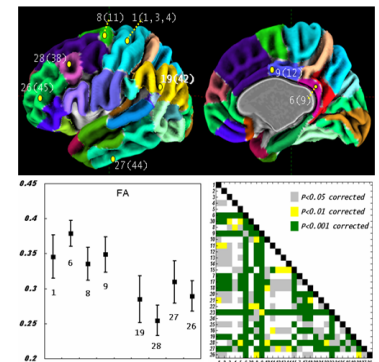


Figure 3: Comparison based on the average FAs between each region. Regions are same as Flechsig's map