

Effect of NBO treatment on lesion volume at early and late reperfusion time points after transient focal cerebral ischemia

J. Ramu¹, W. Liu¹, K. Liu¹, and R. Sood¹

¹Neurology, University of New Mexico, Albuquerque, New Mexico, United States

Introduction

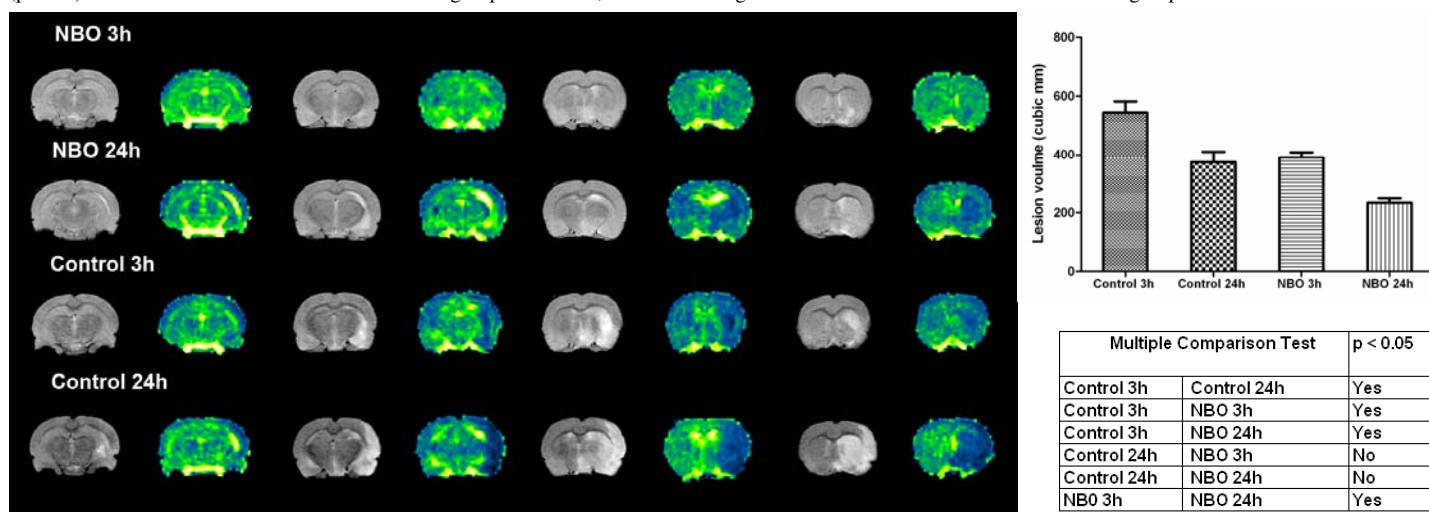
Ischemic stroke is caused by occlusion of cerebral artery due to a thrombus or emboli. A common therapeutic approach for ischemic stroke is the administration of tissue plasminogen activator (tPA), which interestingly is the only FDA-approved acute stroke therapy. Hyperoxia, acting via multiple direct and indirect mechanisms, may be a powerful neuroprotective strategy to salvage acutely ischemic brain tissue and extend the time window for acute stroke treatment. Of the existing oxygen delivery methods, hyperbaric oxygen therapy (HBO) appears to be the most effective, while even normobaric oxygen therapy (NBO) may be effective if started promptly after stroke onset. The development of advanced neuroimaging techniques in the last decade in combination with stroke thrombolysis has renewed the importance of oxygen therapy. Implementation of HBO therapy within the first few hours after stroke onset or in patients with imaging evidence of brain tissue with reversible damage, oxygen therapy could be used to 'buy time' for the administration of thrombolytic or neuroprotective drugs. HBO has so far failed to show efficacy in clinical trials, which is probably attributed to factors such as, delayed time to therapy, inadequate sample size and use of excessive chamber pressures. The goal of this study was to compare the effect of NBO treatment on the lesion volume between early and late reperfusion time points in a rat model of middle cerebral artery occlusion (MCAO).

Materials and Methods

The study was approved by the Local Animal Research Committee and conformed to the NIH guidelines for the use of animals for research. In this study, 24 male Sprague Dawley (250-300g) were divided into 4 groups: 1. Control 3h (N=8), 2. Control 24h (N=8), 3. NBO 3h (N=8), 4. NBO 24h (N=8). Animals in all 4 groups underwent MCAO surgery. The normoxic (control) and NBO rats were ventilated (3 L/min) with medical air (21% O₂) or a gas mixture of 95% O₂ + 5% CO₂, respectively, during the 90-min ischemic period. Isoflurane anesthesia was maintained through a mask and physiological parameters were monitored during the entire duration of the study. MR studies were performed on a dedicated 4.7T MRI scanner (Bruker Biospin Inc, Billerica, MA). After the initial localizer images, multi-slice T2w (anatomical) and diffusion-weighted images (DWI) were acquired in these animals with the following parameters: T2w- TR/TE 4s/65ms, FOV 3.2cm x 3.2 cm, matrix 256x128, number of slices 20, slice thickness 2 mm, #averages 22; DWI- TR/TE 2s/50ms, # averages 15, d = 5ms, D = 20ms, b=0 and 927 s/mm². The DWI images were slice matched to the T2w images. At the end of the MRI experiments, the raw MRI data was transferred to an offline workstation. ADC maps were reconstructed from DWI using commercial software MRVision (MRVision, Winchester, MA). Lesion size was measured using various ADC thresholds and was defined as area with ADC values <80% of the mean contralateral hemisphere values on the ADC map. The analysis was performed by a single operator and the procedure was repeated twice. Lesion size, reported by the software, was calculated as number of pixels x pixel size, where the number of pixels correspond to pixels with values less than the ADC threshold value. Lesion size was estimated per slice and reported as sum over the total number of prescribed slices. These estimates were saved as a text file, read into Excel spreadsheet (Microsoft, Redmond, WA, USA) and used for further analysis. Graphpadprism (Graphpad, Sandiego, CA) was used to perform ANOVA and estimate the statistically significant differences between the groups.

Results

Figure 1 show anatomical (T2w) images and ADC color maps for the four animal groups and clearly demonstrates the ischemic hyperintense lesion on T2w images on the ipsilateral side. On visual inspection of the T2w images, a visible difference between the lesions size can be appreciated on the matching slices. Graph shows the comparison between lesion volumes in the 4 groups. Table shows the significant differences for lesion size between the 4 groups. A statistically significant difference (p<0.05) was observed between treated and control groups. However, there was no significant difference between the NBO treated groups at 3h and 24h.



Discussion

This study clearly demonstrates the direct effect of NBO treatment on the ischemic lesion size. A lack of significant difference between the 2 treated groups, suggest that the effect of oxygen therapy may be possibly independent of the duration of reperfusion. The implications of the following study may provide insight as to a possible mechanism describing the onset of tissue damage and loss typically observed in patients following a stroke. Future studies are required to explain the findings.

References

Hou H et al, The effect of oxygen therapy on brain damage and cerebral pO₂ in transient focal cerebral ischemia in the rat. *Physiol Meas.*2007; 28(8):963-76