

# **MR arterial spin labeling and spectroscopy in patients with Symptomatic internal carotid artery occlusion**

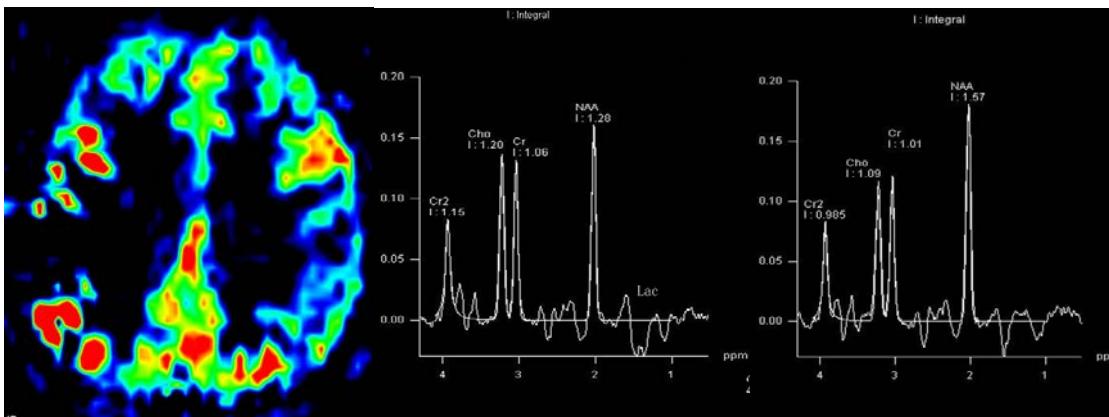
J. Lu<sup>1</sup>, K. Li<sup>2</sup>, and M. Zhang<sup>2</sup>

<sup>1</sup>Xuanwu Hospital, Capital Medical University, Beijing, Beijing, China, People's Republic of, <sup>2</sup>Xuanwu Hospital, Capital Medical University

**ABSTRACT** Arterial Spin Labeling (ASL) is a non-invasive method to quantitatively measure perfusion without the need of contrast material. Measurement of perfusion is derived from the subtraction of two consecutively acquired scans, with or without radio frequency labeling of the magnetization in the feeding arteries<sup>1</sup>. <sup>1</sup>H spectroscopy (<sup>1</sup>H-MRS) can non-invasively identify cerebral abnormal metabolism. Patients with symptomatic occlusion of the internal carotid artery (ICA) with compromised cerebral blood flow (CBF) and decrease *N*-acetyl aspartate (NAA) are at risk for future ischemic infarcts in the brain. In this study, we characterized CBF and the concentrations of choline, creatine, and NAA changes in cerebral white matter in patients with symptomatic ICA occlusion.

**MATERIALS AND METHODS** MR imaging was performed by using a 3.0-T system (Trio Tim, Siemens). Magnetic resonance (MR) imaging with ASL and <sup>1</sup>H-MRS were performed in 28 patients (age, 54.2±14.5; 18 men, 10 women) with unilateral internal carotid artery (ICA) occlusion and in 20 control subjects (age, 52.5±11.6; 12 men, 8 women). The hospital's commission on scientific research on human subjects approved the study protocol, and all study subjects gave informed consent. Imaging parameters of ASL were TR/TE=2500/15 ms, FOV 224 mm×224mm, 6mm thick, 1.5mm gap. Cerebral blood flow (CBF) in the centrum semiovale was calculated from the occluded side and contralateral side. We performed 2 transaxial 2-dimensional proton MRS scans through the semiovale centers to assess metabolite concentrations (TR/TE=1700/135ms; spectral bandwidth, 1500 Hz; 1024 samples)<sup>2</sup>. The entire MRS protocol lasted 12 minutes. Cerebral metabolism was studied by assessing ratios of *N*-acetyl aspartate (NAA) to choline (Cho) and to creatine (Cr) as well as Cho to Cr from centrum semiovale in both hemispheres.

**RESULTS AND DISCUSSION** In the patients with ICA occlusion, CBF decreased were depicted in 18 patients (Fig 1). The mean CBF values were decreased in the centrum semiovale of the ipsilateral hemisphere, as compared with values of the contralateral hemisphere ( $P<0.05$ ) and with values the control subjects ( $P<0.05$ ). The NAA/Cho and NAA/Cr ratios were significantly decreased in the centrum semiovale on the occlusion side (Fig 2) compared with the contralateral side ( $P<0.05$ ) (Fig 3) and control subjects ( $P<0.05$ ). The Cho/Cr ratio was significantly increased compared with contralateral side ( $P<0.05$ ) and control subjects ( $P<0.05$ ). Lactate (Lac) was observed in 3 patients. NAA concentration was positive correlation with CBF; however Cho concentration was negative correlation with CBF. Our result suggested ASL and <sup>1</sup>H-MRS could demonstrate the abnormal cerebral perfusion and metabolic changes in patients with ICA/ MCA high-grade stenosis or occlusion. ASL and MRS may provide a convenient, inexpensive, noninvasive method for identifying ICA occlusion patients at risk for future stroke.



**Figure 1**

**Figure 2**

**Figure 3**

A patient with the right ICA occlusion. ASL image showed CBF decreased on the right hemisphere (Fig1); MRS showed NAA decreased and Cho increased on the ipsilateral hemisphere (Fig 2) than contralateral hemisphere (Fig 3).

## **REFERENCES**

1. Golay X, et al. Neuroimaging Clin N Am, 2006, 16: 259-268.
2. Bisschops RH, et al. Stroke, 2002, 33:110-115.