

# BLADE for T1-weighted contrast with spectral fat suppression: two different approaches for head and neck imaging

C. Fellner<sup>1</sup>, N. Zorger<sup>1</sup>, E. M. Jung<sup>1</sup>, S. Feuerbach<sup>1</sup>, and T. Finkenzeller<sup>1</sup>

<sup>1</sup>Institute of Radiology, University of Regensburg, Regensburg, Germany

## INTRODUCTION:

Up to now, Periodically Rotated Overlapping Parallel Lines with Enhanced Reconstruction (PROPELLER) or BLADE imaging has been applied to reduce motion artifacts mainly in T2-weighted imaging. Using an inversion pulse at the beginning of the sequence results in T1-weighted contrast – this technique has been evaluated for T1-weighted imaging in the brain after application of contrast agent for detection of brain metastases. Contrast-enhanced coronal T1-weighted sequences with spectral fat suppression are an essential part of head and neck MR imaging. But this techniques is extremely susceptible to flow artifacts (neck vessels) and motion artifacts (swallowing) – even in cooperative patients. Therefore, the aim of this study was to evaluate if BLADE imaging might be helpful in a routine clinical setting to improve image quality and diagnostic reliability. Two different approaches to reach T1-weighted contrast in BLADE with spectral fat suppression were tested.

## METHODS:

40 successive patients (26 men, 14 women; 25-80 years old, mean: 59 years) were examined on 1.5 T scanners (Magnetom Symphony TIM and Magnetom Avanto; Siemens) with comparable coil configuration. Three different coronal T1-weighted sequences with spectral fat suppression (after application of 0.1 mmol/kg BW Gd-DTPA) were applied to all patients:

[1] Turbo spin echo (TSE) with conventional rectilinear k-space trajectory ("TSE") and flow compensation in read direction, TR = 607 ms, TE = 10 ms, echo train length (ETL) = 3; [2] TSE with BLADE trajectory ("BLADE"), TR = 607 ms, TE = 23-25 ms, ETL = 9; [3] TSE with BLADE trajectory and preceding inversion pulse ("IR-BLADE"), TR = 2670-2750 ms, TE = 55-56 ms, TI = 860 ms, ETL = 17-19.

Image quality was graded by 2 independent readers on a scale from 1 to 5 (1: excellent, 2: good, 3: moderate, 4: fair, but still diagnostic, 5: non-diagnostic) according to the following criteria: Overall motion artifacts, flow artifacts (ghosting), delineation of thoracic structures, contrast muscle / fat, contrast lymph nodes / fat, and presence of BLADE artifacts. Lesion contrast was evaluated in 25 patients. Results for TSE and BLADE and IR-BLADE were compared using the Wilcoxon test ( $p < 0.05$ ).

## RESULTS:

BLADE and IR-BLADE showed statistically significant better results than TSE for flow artifacts and delineation of thoracic structures, but they were inferior to TSE concerning BLADE artifacts and contrast lymph nodes / fat. For overall motion artifacts and contrast muscle / fat there was no statistical significant difference. Lesion contrast was inferior in TSE compared to BLADE ( $p < 0.5$ ), whereas no statistical significant difference was found between TSE and IR-BLADE (Fig. 1). Nevertheless, one lesion (tongue carcinoma) was missed in IR-BLADE by both readers. The remaining 4 tongue lesions could be delineated with all sequences. There was a trend of improved delineation of lesions of the thyroid gland with BLADE and IR-BLADE, but due to the low number of patients ( $n=5$ ) the difference was not statistically significant.

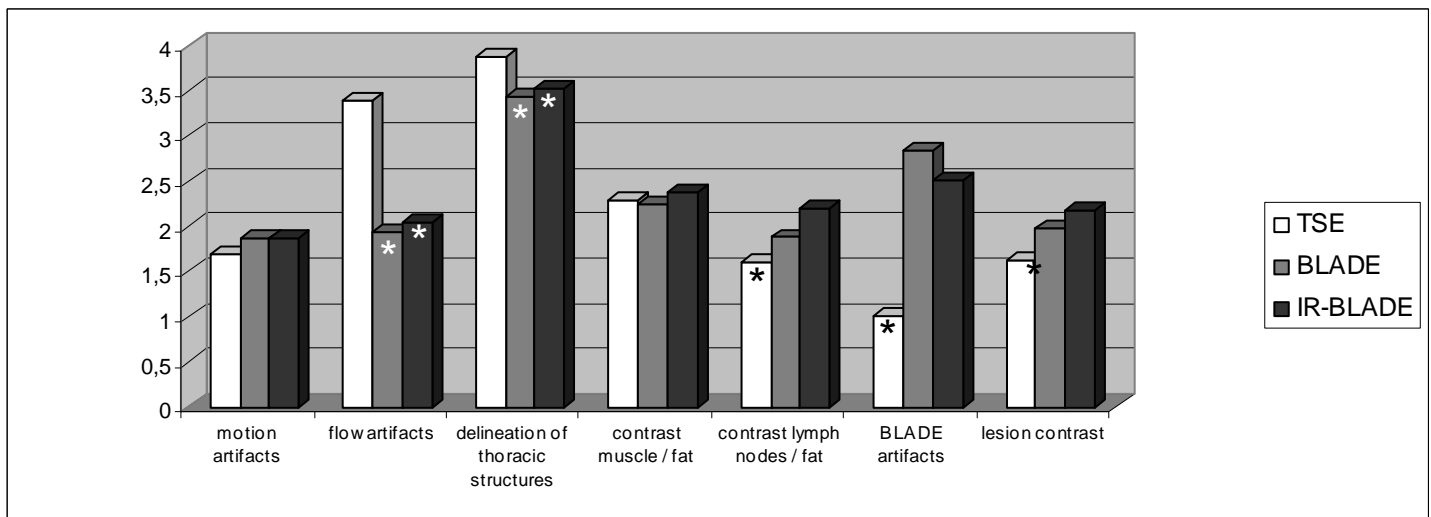


Fig. 1: Results of the visual evaluation on a scale from 1 (excellent) to 5 (non-diagnostic): means of 2 independent readers (\*:  $p < 0.05$ , Wilcoxon test)

## CONCLUSION:

Despite relevant advantages concerning flow artifacts and delineation of thoracic structures our preliminary results indicate that BLADE with a spectral fat suppression pulse can not be generally recommended for T1-weighted head and neck imaging. Both strategies for T1-weighted contrast – either with short TE and an intermediate ETL or with a preceding inversion pulse – revealed disadvantages concerning contrast of anatomical or pathological structures and need further improvement. Nevertheless, BLADE or IR-BLADE might be helpful additionally to conventional TSE imaging in selected cases where motion or flow artifacts are a major problem.