

# Diagnosis of Lumbar Spondylolysis in Children and adolescents on MR imaging: comparison with CT

M. Katayama<sup>1</sup>, T. Masui<sup>1</sup>, K. Sato<sup>1</sup>, H. Ikuma<sup>1</sup>, H. Seo<sup>1</sup>, and A. Kutsuna<sup>1</sup>

<sup>1</sup>Radiology, Seirei Hamamatsu General Hospital, Hamamatsu, Shizuoka, Japan

## Purpose

Spondylolysis is defined as a bone defect in the pars interarticularis and is one of the most popular causes in the patients who have lumbago in childhood and adolescence. The pathogenesis of spondylolysis is considered to be stress fracture. Findings of spondylolysis on conventional radiographs and on CT images have been well characterized. However, these images need irradiation. MR imaging, which needs no irradiation, may have been used as one of the primary screening methods in these patients. Although the early stage of spondylolysis might be detected in MR imaging, we have no gold standard technique. On the other hand, MR findings of pars interarticularis may be not specific for spondylolysis which was confirmed in CT imaging. In this study, we evaluated MR findings in the pars interarticularis that in patients with spondylolysis was confirmed on CT images.

## Methods

41 children and adolescent patients (34 men and 7 women, age range: 11 - 21, mean age 15.3 years old), suspected of having spondylolysis, who underwent CT scans and lumbar spinal MRI using 1.5T unit (SIGNA, GE, 61 female patients. MR examination was consisted of sagittal and coronal spin-echo T1-weighted images without fat saturation (TE / TR: 12 - 15 / 600msec, slice thickness / interslice gap: 4 - 5 / 1mm, FOV: 20 - 30 cm, respectively), and transverse, sagittal and coronal spin-echo T2-weighted images with fat saturation (TE / TR: 80 90 / 5000 msec, slice thickness / interslice gap: 4 - 5 / 1 mm, FOV: 20 - 30 cm, respectively). When the existence of spondylolysis was suspected of in MR imaging, CT images were acquired in the reverse-angle axial plane at the objective lumbar spine levels on multi-detector-row CT (LightSpeed, GE). Approximately fifteen contiguous sections were acquired at each level with 1.25 mm slice thickness. All images were reviewed on a monitor display. The findings of the pars interarticularis at both sides were the following points: existence or absence of change of signal (high, low or iso signal intensity in MR imaging, and high or iso attenuation in CT imaging, respectively), and existence or absence of bone defect or fracture line, respectively. Furthermore, in MR imaging we assessed other findings such as disc herniation, spondylolisthesis, and inflammation around the par interarticularis, respectively.

## Results

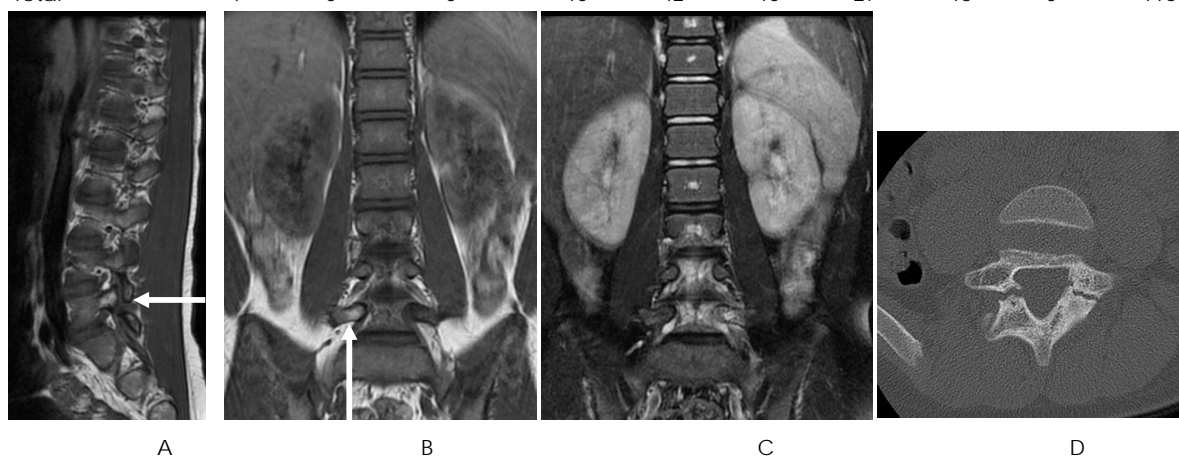
Disc herniation was observed in 5 of 41 patients, while spondylolisthesis were observed in none of these patients. A total of 116 pars interarticularis of lumbar spine were evaluated in CT and MR imaging. Spondylolysis (bone defects) were confirmed in 46 pars interarticularis in CT imaging. High attenuations (suggested of sclerotic change) without bone defects in CT imaging were observed in 55 pars interarticularis. The results are summarized in Table 1. In T1-weighted imaging, 4 of 4 (100%) pars interarticularis that showed high signal intensity had spondylolysis with CT images. Of 46 pars interarticularis that had spondylolysis with CT images, 34 (73.9%) pars showed high signal intensities in T2-weighted MR imaging, while 22 (47.8%) pars showed bone defects or fracture lines and 8 (17.4%) pars showed no findings in T1 or T2 weighted MR imaging.

## Discussion and Conclusion

In MR imaging signal intensities in pars interarticularis showed various. Although High signal intensities in T2-weighted imaging and low signal intensities in T1-weighted imaging were clues to spondylolysis, 17.4 % of pars interarticularis had no abnormal findings. High signal intensities in T1-weighted imaging, which was low frequency, might be a clue to spondylolysis.

**Table 1.** Combined evaluation with T1- and T2-weighted MR imaging and CT imaging

T1WI	Hyper-intensity			Iso-intensity			Hypo-intensity			total	
	CT findings	defects	sclerosis	normal	defects	sclerosis	normal	defects	sclerosis		normal
Hyper-intensity on T2WI		0	0	0	7	5	2	27	12	0	53
Iso-intensity on T2WI		2	0	0	8	36	13	0	0	0	59
Hypo-intensity on T2WI		2	0	0	0	1	0	0	1	0	4
Total		4	0	0	15	42	15	27	13	0	116



**Figures.** An 11-year-old boy with bilateral L5 spondylolysis. Sagittal (fig. A) and coronal (fig. B) T1-weighted images show high signal intensities in the right (arrow), and low signal intensity in the left pars interarticularis. Coronal T2-weighted (fig. C) images show iso intensity in the right, and high signal intensities in the left pars interarticularis. CT image (fig. D) shows bilateral bone defect in the L5 pars interarticularis.