

## Structural deficit in remitted and non-remitted recurrent depression: A voxel-based morphometric study

P-C. Chen<sup>1</sup>, K-H. Chou<sup>2</sup>, I-Y. Chen<sup>3</sup>, H-H. Wang<sup>1</sup>, C-T. Li<sup>4</sup>, T-P. Su<sup>4</sup>, and C-P. Lin<sup>1,3</sup>

<sup>1</sup>Institute of Biomedical Imaging and Radiological Sciences, National Yang-Ming University, Taipei, Taiwan, <sup>2</sup>Institute of Biomedical Engineering, National Yang-Ming University, Taipei, Taiwan, <sup>3</sup>Institute of Neuroscience, National Yang-Ming University, Taipei, Taiwan, <sup>4</sup>Department of Psychiatry, Taipei Veterans General Hospital, Taipei, Taiwan

### Introduction

Major depressive disorder (MDD) is increasingly recognized as a chronic and deteriorating disorder, also associated with high medical and other psychiatric comorbidity [1]. Without sufficient treatment to achieve fully remission, residual symptoms of depression would lead to poorer outcome including higher relapse or recurrence rates and suicidality, lower quality of life and more deteriorated psychosocial functioning [2-4]. However, not every depressed patient showed equally good response to antidepressants. Compared to responders, patients who failed to respond to antidepressants showed different functional patterns in the brain [4]. In order to further investigate macrostructure difference between remission and non-remission MDD patient groups, T1 Voxel Based Morphometry (T1-VBM) were performed to clarify whether any structure differences among remitted/non-remitted MDD subjects and healthy subjects.

### Material and Methods

Recurrent 44 MDD patients were in relative stable clinical conditions after antidepressant with adequate dosage and duration (at least 4 weeks). Diagnoses were established by Mini international Neuropsychiatric interview based on the DSM-IV criteria. All the patients were further subcategorized into 2 groups: remitted MDD and non-remitted MDD groups. Remission was defined as 17-item Hamilton Depression Rating Scales (HDRS-17) scores equal or lower than 7. Hence, 25 non-remitted MDD patients (mean age: 46.28±10.59 y/o, 20 female and 5 male), 19 remitted patients (mean age: 42.16±13.18 y/o, 13 female and 6 male) and 25 healthy controls (mean age: 40.28±12.79 y/o, 19 female and 6 male), were recruited in this study. These three groups were matched in age, gender, and handedness. All MR scans were performed on a 1.5T MR system (Excite II; GE Medical Systems, Milwaukee, Wis., USA) at the Veterans General Hospital Taipei. Whole brain T1-weighted images were acquired using 3D FLAIR-FSPGR with TR/TE= 8.54/1.84ms, TI= 400ms, Flip angle =15°, voxel size=1.02\*1.02\*1.5 mm<sup>3</sup> and NEX=1. An optimized T1-VBM protocol [5] was used in this study. All image preprocessing were performed on the SPM2 (Wellcome Department of Imaging Neuroscience, London, UK). The data preprocessing followed a number of defined steps as the following: (1) creation of group-specific templates and priors. (2) segmentation of native scans and deviation of optimize normalization parameter. (3) optimized normalization and segmentation. To investigate the voxel-wise gray matter volume differences among three groups, the analysis of covariance (ANCOVA) were employed while grey matter volume as the dependent variable at each intracerebral voxel in standard space, covarying with the total intracranial volume (TIV), ages, and degrees of education. An uncorrected p-value < 0.005 as well as a cluster size more than 15 contiguous voxels was set to putatively detect the significant between-group differences.

### Results

#### Regional Gray Matter reduction between Non-Remitted/Remitted MDD and Healthy Subjects :

Non-remitted MDD group demonstrated more reduced GMV in left thalamus, left dorsolateral prefrontal gyrus (Brodmann area (BA) 9) and left precentral frontal gyrus (BA 4) than healthy subjects (Fig 1). Remitted MDD group showed reduced GMV in right medial frontal gyrus (BA 6), left superior frontal gyrus (BA 6) and medial part of left postcentral parietal gyrus (BA 3) than healthy subjects (Fig 2).

#### Regional Gray Matter reduction between Non-Remitted MDD and Remitted MDD Subjects :

Patients achieving symptomatic remission had larger GMV in right occipital lobe, cuneus (BA 19), right temporal fusion gyrus (BA 36), left superior frontal gyrus (BA 9) and left postcentral parietal gyrus (BA 3) than non-remitted patients.

### Conclusions

Our finding suggested that the remitted MDD patients reduced GMV in left BA 3 and bilateral BA 6 compared to normal control. The gray matter volume reduction in these areas might account for some cognition deficits in remitted MDD patients, like planning of complex, storing and manipulating information. The non-remitted patients showed more structural abnormalities than normal and remitted patients, including reduced GMV over the left prefrontal and frontal cortex, right temporal, and occipital cuneus, the result was consistent with previous study [6], and abnormal metabolism over left DLPFC (BA 9) has found to be critical in depression from past functional studies [7-8]. Past investigations have shown that longer duration of depression would contribute to reductions in total brain volume, this possibly explained why the reduction of GMV in the left DLPFC was only observed in the non-remitted patients. Our results indicated not all MDD groups present the same morphological deficits in the brain. Furthermore, it implicated that severity of depression and patients' response to antidepressants should be also taken into consideration when investigating structural alterations in MDD.

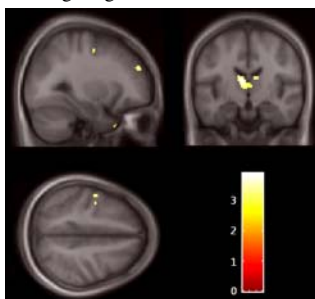


Figure 1.

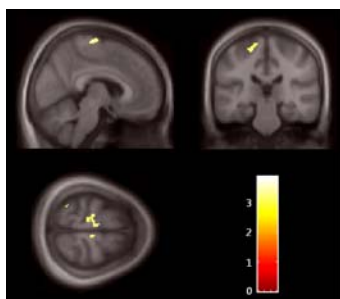


Figure 2.

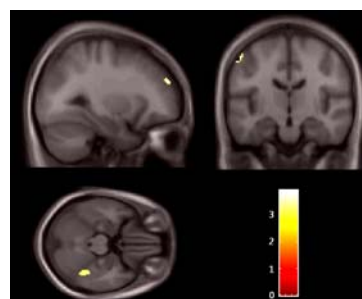


Figure 3.

#### Figure 1 : Volume differences between Normal and Non-Remitted patients (Normal > Non-Remitted )

Comparing to normal, non-remitted MDD patients has smaller gray matter in left thalamus (Top-Right), left dorsolateral prefrontal gyrus (Top-Left) and left precentral frontal gyrus (Bottom-Left).

#### Figure 2 : Volume differences between Normal and Remitted patients (Normal > Remitted )

Comparing to normal, remitted MDD patients has smaller gray matter in right medial frontal gyrus (Top-Left), left superior frontal gyrus (Bottom-Left) and medial part of left postcentral parietal gyrus (Top-Right).

#### Figure 3 : Volume differences between Remitted and Non-Remitted patients (Remitted > Non-Remitted )

Comparing to normal, non-remitted MDD patients has smaller gray matter in left postcentral parietal gyrus (Top-Right), right temporal fusion gyrus (Bottom-Left) and left superior frontal gyrus (Top-Left).

### Acknowledgements

The study was supported by grants from National Science Council, Taiwan (NSC 96-2314-B-075-009 and NSC 97-2752-B-075 -001), and Taipei Veterans General Hospital (V97C1-061).

### References

- [1]Roose SP et al, *Jama*. 2001. [2]Tranter R et al, *J Psychiatry Neurosci*. 2002. [3]McCall WV et al, *Psychiatry research*. 2003. [4]Mayberg HS et al, *Biological psychiatry*. 2000. [5] Ashburner J et al., *Neuroimage*. 2000. [6] Vasic N et al, *Journal of affective disorders*. 2008. [7] Drevets WC et al, *Curr Opin Neurobiol*. 2001. [8] Siegle GJ et al, *Biological psychiatry*. 2007.