

# Pre-surgical Mapping of Paediatric Motor Function and Structure using Magnetoencephalography (MEG) and Diffusion Tensor Imaging (DTI)

D. Mabbott<sup>1</sup>, N. Scantlebury<sup>1</sup>, C. Rockel<sup>1</sup>, E. Widjaja<sup>1</sup>, and W. Gaetz<sup>1</sup>

<sup>1</sup>Hospital for Sick Children, Toronto, Ontario, Canada

**Introduction and Purpose:** The presence of space-occupying lesions in the brain often causes the displacement of tissue from its normal location. Accordingly, surgical resection of these lesions requires a detailed understanding of the functional and structural anatomy of the adjacent tissue. Methods such as direct electrical cortical stimulation (ECS), functional MR imaging (fMRI) and magnetoencephalography (MEG) have been used to decipher the functional organization of the cortex. These techniques enable the resection of diseased neural tissue, while ensuring that eloquent motor cortex is avoided. With the advent of diffusion tensor tractography, the pre-surgical localization of the cortical-spinal tracts (CSTs) associated with motor cortex has also been demonstrated in adults. It is difficult to generalize the adult literature to children due to the plasticity of the immature brain and propensity for functional reorganization in response to pathology, however. As such, mapping cortical motor fields in children and identifying the CSTs associated with these fields is essential. Recently, innovations in MEG source localization have been applied to localize motor function. By coupling new beamformer techniques in MEG (ERB) with diffusion tensor imaging (DTI) methodologies, the identification of functional pathways in children is possible. The concurrent use of MEG and tractography methods has the potential to better account for the impact of plasticity in the developing brain on CST location. We used these new MEG mapping methods in combination with DTI tractography to delineate motor cortex and associated CST for patients with hemispheric lesions (prior to surgery) and healthy age-matched control children.

**Subjects and Methods:** Participants were 5 patients (mean age = 11.97 ± 3.5) and 5 age-matched control children (mean age = 11.76 ± 4.03). First, MEG data were acquired: Bi-polar EMG electrodes were placed at the left and right First Dorsal Interosseous (FDI) muscles. Subjects moved right and left index fingers separately, following a visual target. Transient movements were performed once every 4s (on average) for a total of 100 movements/side. ERB was used to localize the cortical responses known to accompany transient finger movement. Second, diffusion data were acquired with a GE LX 1.5T MRI scanner using a single shot spin echo EPI DTI sequence (15 – 25 directions, b=1000s/mm<sup>2</sup>, TE/TR=84.7/10,000 ms, 42 contiguous axial slices, 2-3 mm isotropic, 128 x 128 matrix, FOV = 24cm, rbw = 125 kHz, NEX = 1). Subsequently, MEG activations were marked on the T1 anatomical scan, which were non-linearly registered with the DTI sequence. Motor field activations were then used to seed probabilistic tractography of the CST on both the left and right sides, with way-ward seeds through the posterior internal capsule. Seed size was standardized across subjects. The resulting tracts were thresholded to eliminate non-robust probabilities by removing voxels within the lowest 10%. Tracts from the motor-activation seeds of the 5 control subjects were linearly registered into a common space where, together, they formed a template designated as “normalized” space. The template was used to evaluate displacement of the CST by the lesion present. In addition, the left and right CST were used as regions of interest to extract mean FA, ADC, 1<sup>st</sup>-, 2<sup>nd</sup>- and 3<sup>rd</sup>-eigenvalues. Group differences for all DTI measures were examined between the patient and control groups using one-way analyses of variance for the CST on the affected side and on the unaffected side.

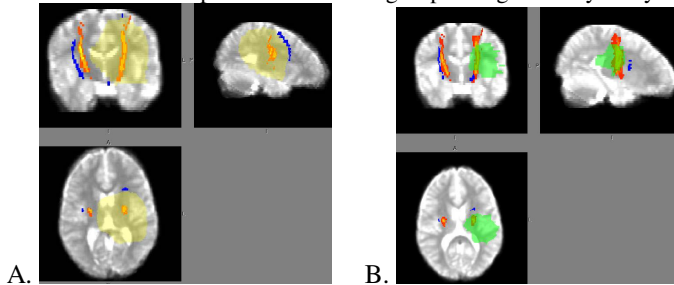


Figure 1. Two cases of CST displacement by centrally-located tumors

**Results:** The CST on the affected side for patients 1 (Fig. 1A; blue) and 3 (Fig. 1B; blue) were substantially displaced anterior to the normalized anatomy (orange) due to the presence of a large, centrally-located tumor (yellow/green). The CSTs on the unaffected side were also displaced laterally from their normalized location, presumably due to mass effect of these large tumors. In patients 2 and 4, where tumors were not centrally-located, neither the CST on the affected nor unaffected side was displaced relative to the normalized CST. One of the functional motor seeds was displaced to the contra-lateral side in patient 5, who presented with a large arteriovenous malformation and residual encephalomalacia. For most patients, there was little overlap in the CSTs that were produced by motor versus anatomical seeds. Furthermore, motor seeds provided more localized and specific tracts in comparison to anatomical seeds. Based on univariate comparisons for the CST seeded from motor activations, mean FA, ADC and parallel diffusivity (1<sup>st</sup> eigenvalue) were significantly higher in the CST of the affected side in patients relative to controls (Table 1). Perpendicular diffusivity did not differ between the groups. No group differences were evident for any DTI indices seeded from anatomical locations (Table 1).

Index	Seed	Patient		Controls		Statistics	
		Mean	S.D.	Mean	S.D.	F	p
FA	Motor	.52	.04	.46	.03	5.21	.05
FA	Anatomical	.52	.04	.49	.03	2.40	.16
ADC	Motor	.0008	.00006	.0007	.00005	6.15	.04
ADC	Anatomical	.0008	.00006	.0007	.00004	3.10	.12
1 <sup>st</sup> Eigenvalue	Motor	.0013	.00012	.0011	.00010	6.38	.04
1 <sup>st</sup> Eigenvalue	Anatomical	.0013	.00010	.0012	.00086	3.79	.09

Table 1. DTI measures for the CST on the affected side comparing patient and control groups using one-way analyses of variance.

**Conclusions:** We investigated the clinical efficacy of using concurrent MEG-DTI methods to delineate the functional motor pathways of children seen for pre-surgical evaluation, and demonstrated the validity of using this technique to characterize the displacement of CST by space-occupying lesions. We report a significant increase in the FA, ADC and parallel diffusivity of motor-seeded CST for patients in comparison to controls. The increase in water diffusion parallel to the CST likely reflects the enhanced compression and flattening of the tract by the lesion. Functional seed activations generated more localized and specific tracts than anatomical seeds. Furthermore, functionally-seeded CST appear to be more sensitive to the changes in tissue micro-structure than anatomically-seeded tracts. These findings reinforce the importance of using the functional seed in localizing CST, especially when considering plasticity in the developing brain.