

Evaluation for MTBI and DAI by using Voxel-Based Diffusion Tensor Imaging

K. Kasahara¹, M. Abo², K. Hashimoto², A. Senoo¹, and T. Kodama³

¹Graduate School of Human Health Science, Tokyo Metropolitan University, Tokyo, Japan, ²Department of Rehabilitation, Jikei Medical School, Tokyo, Japan, ³Div. of Radiation Therapy Physics, Chiba Cancer Center

Introduction: In Japan, there are approximately 280,000 new cases of traumatic brain injury (TBI) each year, with at least 80% being classified as mild. The diagnosis and management of mild traumatic brain injury (MTBI) continues to be the subject of debate, with varying opinions regarding the extent to which organically based impairments vs the impact of other stressors cause ongoing disability. Detecting areas of the brain with abnormalities that can explain symptoms and behavior in patients with MTBI is important in order to confirm the diagnosis of MTBI. Several studies have recently reported the effectiveness of diffusion-weighted imaging (DWI) for evaluation of diffuse axonal injury (DAI) and MIBI. Diffusion tensor imaging (DTI), a relatively novel MRI technique, is designed to detect more extensive abnormalities than conventional MRI in patients with severe head injury, and the findings of DTI have been reported to correspond with clinically determined neurological deficit. In this study, we make the apparent diffusion coefficient (ADC, λ_{\perp} , and λ_{\parallel}) maps and the fractional anisotropy (FA) maps calculated from DTI in control group. And we compared each maps in MIBI group and DAI group with these.

Materials and Methods Subjects: 6 DAI patients (Glasgow Coma Scale (GCS): 4.00 ± 0.71 and Japan Coma Scale (JCS): 2, age: 38.0 ± 8.25 , mean time to imaging following injury: 1 - 10 years) and 12 MTBI patients (GCS: 14.8 ± 0.44 and JCS: 2 and 3, age: 40.0 ± 11.2 , mean time to imaging following injury: 2 - 12 years) and 13 healthy adult volunteers (ages 25.1 ± 8.73) were imaged with conventional MRI and DTI. Informed consent was obtained from all subjects after procedure had been fully explained and the study was approved by the Internal Review Board of the Jikei Univ. School of Medicine Hospital.

MRI experiments: The imaging uses a 1.5T MRI device (Siemens, Symphony); Spin-echo type Diffusion weighted EPI, TR/TE: 5400/99[ms], MPG64 axis (b-value 1,000 [s/mm²]: 60, b-value 0 [s/mm²]: 4), Matrix size: 128×128, FOV: 24×24[cm²], a slice thickness: 3.3[mm], NEX: 1. We used software MediPACK that we made for distortion correction and diffusion tensor analysis and used SPM2 for statistical analysis.

Results and Discussions

Figure 2 shows statistical parameter maps resulted from VBM analysis of FA and λ_{\perp} map for DAI and MTBI patients compared to control group.

In DAI patients, region of decreased FA values were mainly observed in the corpus callosum ($p < 0.001$). The region of brain injury in DAI appears in the corpus callosum, brainstem, internal capsule, and deep white matter. We found that the distribution of these FA decreases was similar to the distribution of brain injury. In MTBI patients, the distribution of increased λ_{\perp} was observed localized region in white matter of frontal lobe.

Figure 3 shows regional FA and λ_{\perp} values for DAI and MTBI patients compared to control group. DAI patients showed significant difference of FA and λ_{\perp} values compared to control group ($p < 0.001$). MTBI patients didn't show significant difference of FA values but showed significant difference of λ_{\perp} values compared to control group ($p < 0.001$). The difference of injury details between DAI and MTBI is unclear. However, our results obtained from VBM analysis of λ_{\perp} values may be helpful for diagnosis of MTBI.

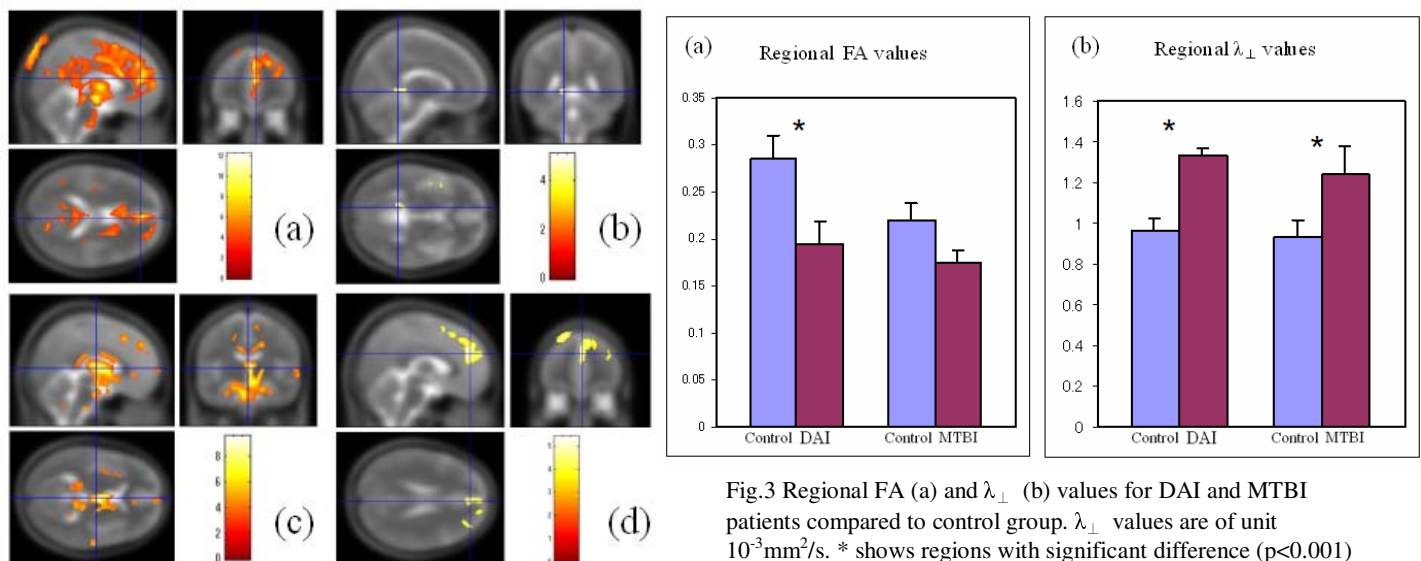


Fig.3 Regional FA (a) and λ_{\perp} (b) values for DAI and MTBI patients compared to control group. λ_{\perp} values are of unit 10^{-3} mm²/s. * shows regions with significant difference ($p < 0.001$) between patients and control group.

Fig.2 Statistical parameter maps;
(a) FA-DAI, (b) FA- MTBI, (c) λ_{\perp} -DAI, (d) λ_{\perp} -MTBI

Conclusion

The diagnosis and management of MTBI continues to be a subject of debate, with varying opinions regarding the extent to which organically based impairments versus the impact of other stressors cause ongoing disability. MTBI was observed as no change in conventional MRI, but we were able to identify abnormalities by using VBM analysis of λ_{\perp} values. This method will be effective tool for diagnosis of higher brain dysfunction.

References Sheng-Kwei Song et al. Demyelination increases radial diffusivity in corpus callosum of mouse brain *NeuroImage* 2005;26:132-140