

Discrimination of distinct patterns of myelin-associated parameters in hypomyelinating white matter disorders by multimodal quantitative MR-Imaging

S. Dreha-Kulaczewski¹, K. Brockmann¹, M. Henneke¹, C. Zuercher¹, P. Dechent², J. Gaertner¹, and G. Helms²

¹Department of Pediatrics and Pediatric Neurology, Georg August University, Goettingen, Germany, ²MR-Research in Neurology and Psychiatry, Georg August University, Goettingen, Germany

Introduction

Myelin-sensitive quantitative MRI techniques are of growing interest in pediatric research. Amongst childhood leukoencephalopathies, hypomyelinating disorders constitute a large single category [1]. We studied five patients with defined hypomyelinating leukodystrophies using magnetization transfer (MT) and diffusion tensor imaging (DTI) providing parameter maps related to myelination. The purpose was i) to validate those pathological changes and ii) to identify distinct myelin patterns for the defined hypomyelinating WM disorders in order to derive/establish criteria for further differentiation of undefined disorders.

Patients and Methods

One girl with a mitochondrial cytopathy (Mito Cyto) (1.6 yrs) due to complex IV-deficiency, two boys with the clinical/neuroradiological diagnosis of Hypomyelination with Atrophy of the Basal ganglia and Cerebellum (HABC) (11.2; 12 yrs), and two siblings with *GJA12*-related Pelizaeus-Maerzbacher-like disease (PMLD) (girl 11 yrs; boy 18.6 yrs; both with homozygote mutation p.[Leu28ArgfsX 16]) [2] were investigated at 3 T. MRI was performed using a 3T clinical scanner (TRIO, Siemens, Erlangen). High-resolution 3D MRI (T1-w(eighted) MP-RAGE, T2-w variable flip-angle TSE, and FLAIR), DTI (single-shot STEAM MRI at 2.2 mm resolution, $b=950$ s/mm², 24 gradient directions, 2.2 mm slice thickness) and 3D MT imaging at 1.25 mm isotropic resolution (3D FLASH, TE/TR/ $\alpha=4.9/25$ ms/5°; 12.8 ms Gaussian MT-pulse of 540° applied 2.2kHz of resonance). By means of two reference FLASH scans with predominant PD-w (TR/ $\alpha=25$ ms/5°) and a T1-w (TR/ $\alpha=11$ ms/15°), we obtained the map of the percentage MT saturation caused by a single MT-pulse, a novel semi-quantitative MT parameter that is insensitive to T1 and RF inhomogeneities [3].

Results

All techniques revealed widespread alterations in WM (Fig. a-c upper trace), in particular loss of fractional anisotropy (FA) and reduced MT saturation (Fig. a-c middle trace) in comparison with a healthy control (Fig. d upper, middle trace). MT histograms (Fig. a-c lower trace) showed absence of the high MT mode ascribed to myelinated WM in controls (Fig. d lower trace). The histograms of the HABC and *GJA12*-related PMLD patients were similar (Fig. b,c lower trace), but discriminative patterns emerged on pseudo-colour MT saturation maps (Fig. b,c middle trace). In HABC patients, reduced MT saturation was mainly seen in deep periventricular WM, and uniformly in the corpus callosum (Fig. b middle trace). In *GJA12*-related PMLD the most prominent loss of MT saturation was in deep periventricular WM, U-fibres, and only in parts of the corpus callosum. Especially the centrum semiovale and pyramidal tracts seemed less affected (Fig. c middle trace). The alterations were more pronounced in the girl with the more severe clinical symptoms. The patient with Mito Cyto (Fig. a middle trace) showed a severe and uniform loss of MT saturation. MT saturation correlated well with FA, but FA maps did not enable such detailed spatial evaluation and differentiation of parenchyma and CSF. Furthermore MT saturation correlated better with clinical severity than FA.

Discussion and Conclusion

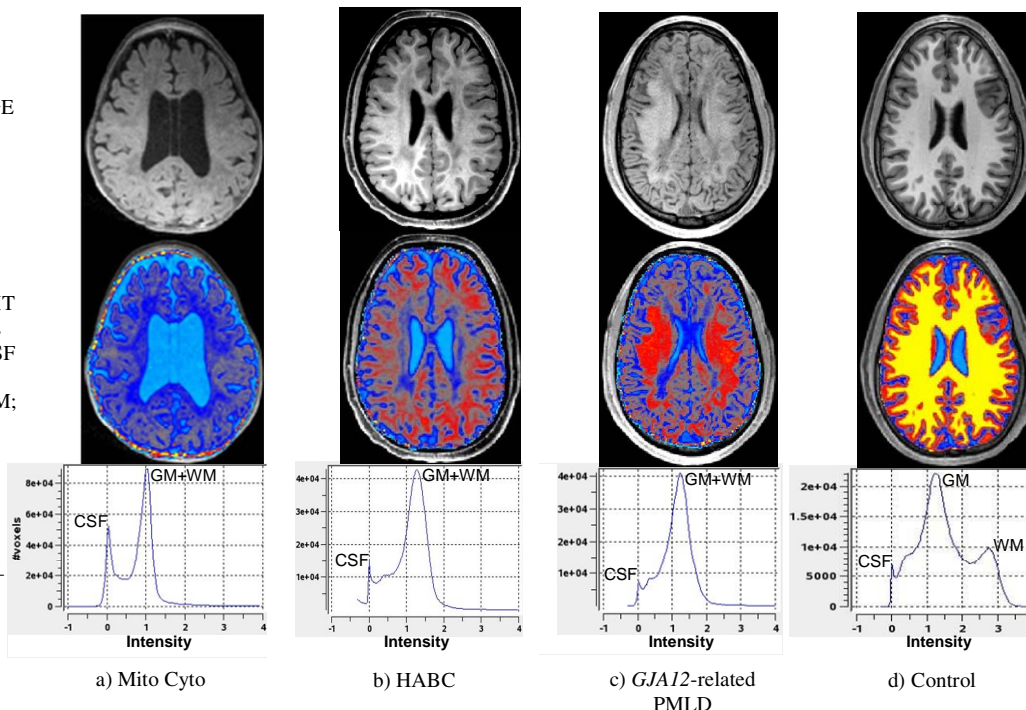
About half of the MT saturation in healthy WM can tentatively be ascribed to myelin that is composed of structured macromolecules. In healthy adults, higher MT values (red to yellow) correlate to the short-T2 component of myelin water [4]. On the other hand, MT is reduced by edema. Thus, MT maps provided a graded contrast in regions of higher water content (blue). In summary, among the applied quantitative MR parameters associated with myelination, the MT saturation provided the best contrast. Hence MT may add information for further differentiation of the undefined WM disorders.

Figure :

Upper trace:
T1-w MP-RAGE
image

Middle trace:
colour coded MT
saturation maps
(cyan-0.3%: CSF
blue 0.5%,
grey 1.35%: GM;
red 2.0%,
yellow 2.8%:
WM)

Lower trace:
histogram of
MT saturation –
intensity in
percent units



References:

- [1] van der Knaap MS, et al.; *Radiology*, 1999, 213:121.
- [2] Henneke, M et al.; *Neurology*, 2008, 70:748.
- [3] Helms G, et al.; *MRM*, 2008, in press.
- [4] Helms G, et al.; White Matter Study Group Meeting 2008.