

Improved correlation of composite MRI scores with EDSS in Multiple Sclerosis

A. H. Poonawalla¹, S. Datta¹, V. Juneja¹, F. Nelson², J. Wolinsky², G. Cutter³, and P. Narayana¹

¹Diagnostic and Interventional Imaging, University of Texas Medical School at Houston, Houston, TX, United States, ²Neurology, University of Texas Medical School at Houston, Houston, TX, United States, ³Biostatistics, University of Alabama at Birmingham School of Public Health, Birmingham, AL, United States

INTRODUCTION. In order to monitor treatment efficacy and disease progression in multiple sclerosis (MS), quantitative MRI metrics are sought that will correlate with patient disability, typically assessed according to the qualitative and ordinal Expanded Disability Status Scale (EDSS) [1]. Conventional MRI metrics include contrast-enhanced lesion volume, lesion hyper-intensity on T2-weighted images, hypo-intensity on T1-weighted images (“black holes”), and brain atrophy. However, the correlation with EDSS using individual MRI metrics such as these is poor [2, 3], due to confounding factors including lesion heterogeneity, patient variability and technical limitations in imaging subclinical disease. Composite scores comprised of multiple MRI measures are an improvement, but still provide only modest correlation with EDSS [4], suggesting that conventional metrics alone do not provide a broad enough characterization of the disease. In this work, we develop novel composite scores incorporating mean T2 values for white matter, gray matter, lesions, and lesion components in addition to conventional metrics, and assess their performance.

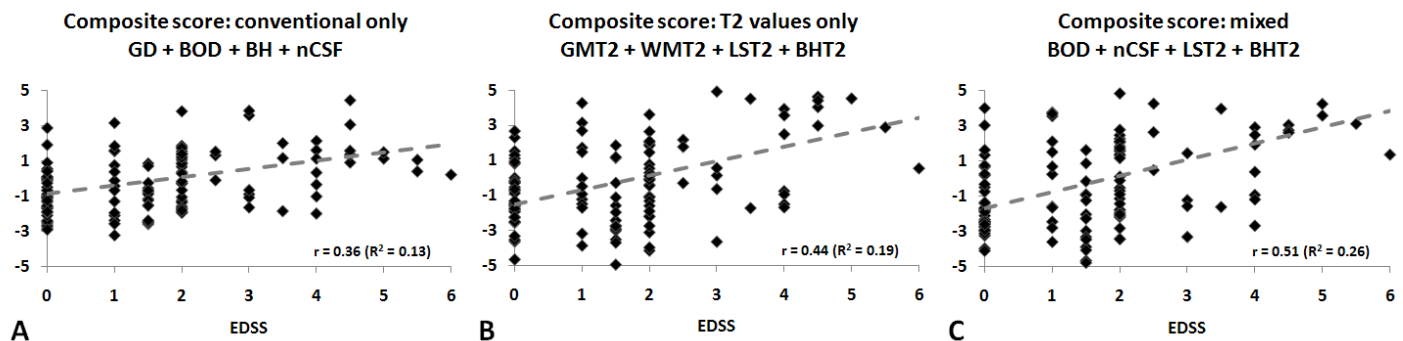
METHODS. 139 consenting patients (113 female, 26 male) with relapsing-remitting MS (RRMS), median age 43 years (20 – 64), and median EDSS score of 2.0 (0 – 6) were imaged on a 3T MRI scanner using a 6-channel SENSE head coil (Philips Medical Systems, Best, Netherlands). The acquisition included dual-echo FSE, FLAIR, and pre/post-Gd contrast T1-weighted images. All images had in-plane resolution of 0.94 mm x 0.94 mm and 44 contiguous axial slices of 3.0 mm thickness.

MRI images were segmented by an automated algorithm [5] to derive Gd-enhancing tissue volume (GD), total lesion volume “burden of disease” (BOD), lesion-only components of T2-hyperintense and black hole (BH) volumes, and normalized CSF volume fraction (nCSF). Voxel-wise T2 values were computed from the dual-echo FSE images as $(TE_2 - TE_1) / \ln(S_1/S_2)$, where TE_1 & TE_2 are the echo times and S_1 & S_2 the respective signal intensities. Mean T2 values for the white-matter (WMT2), gray-matter (GMT2), black hole (BHT2), and lesion (LST2) compartments were then computed using the segmentation masks. All measures were standardized to dimensionless units of deviation from the mean using the z-transform $(x - u) / \sigma$, where u and σ are the mean and standard deviation of each metric over the patient population.

The correlations of all measures with EDSS and cross-correlations between pairs of individual measures were computed using Pearson’s correlation coefficient. These were used to guide the construction of composite scores, to ensure individual components correlated strongly with EDSS (to maximize sensitivity) and cross-correlation between components was low (to maximize information). Pearson’s correlation coefficient was then used to assess the performance of the final composite scores with EDSS. Unitary weighting of components was assumed, though in principle the weighting could be further optimized by regression analysis.

RESULTS. Correlation of individual measures and T2 values are listed in Table 1. The correlation of composite scores with EDSS ranged from $r = 0.361$ ($p < 0.0001$) for scores entirely comprised of conventional measures, to $r = 0.438$ ($p < 0.0001$) for scores entirely comprised of T2 values, to $r = 0.512$ ($p < 0.0001$) for a mixed composite score including both types. Scatter plots of EDSS score versus (dimensionless) composite score are shown in Figure 1 below.

Table 1. Quantitative measure correlations w/EDSS	rho	p
GD - Contrast-enhancing lesions volume (cc)	0.077	0.368
BOD - Total lesion volume (cc); combined T2 hyperintense non-BH and BH lesional components	0.379	<0.001
BH - Black hole volume (cc)	0.022	0.797
nCSF - Normalized CSF volume	0.370	<0.001
WMT2 - Mean T2 of white matter (ms)	0.355	<0.001
GMT2 - Mean T2 of gray matter (ms)	0.235	0.005
LST2 - Mean T2 of T2 lesions (ms)	0.408	<0.001
BHT2 - Mean T2 of black-holes (ms)	0.415	<0.001



DISCUSSION. The inclusion of quantitative T2 values in composite scores results in a dramatic improvement in correlation with EDSS, most likely due to the inherent sensitivity of T2 to microscopic disease processes, which complements the conventional measures (which are more macroscopic in scope). The combination of conventional measures and T2 is also more robust against the degrading effect of increased population size (due to greater variability). Our lowest observed correlation of 0.36 exceeded that in other studies of comparably-sized cohorts [6]. Therefore, mixed composite scores including T2 appear to be particularly well-suited for large studies and multicenter trials.

REFERENCES. [1] Zivadinov R et al. J Neuroimaging. 2005;15:10S-21S. [2] Barkhof Z. Curr Opin Neurol. 2002;15:239-245. [3] Barkhof F. Mult Scler. 1999;5:283-286. [4] Wolinsky JS et al. Neurology. 2000;54:1734-1741. [5] Datta S et al. Neuroimage. 2006;29:467-474. [6] Fisher E et al. Neurology. 2002;59:1412-1420.