

Elevated myo-inositol reflects activation of astroglia and microglia in cognitive impaired HIV patients

U. Feger¹, M. Ricardo- Dukelow¹, T. Ernst¹, V. Nerurkar², E. Volper², S. Buchthal¹, H. Nakama¹, and L. Chang¹

¹University of Hawaii, JABSOM, Neuroscience and MR Research Program, Honolulu, HI, United States, ²University of Hawaii, JABSOM, Asia-Pacific Institute of Tropical Medicine and Infectious Diseases, Honolulu, HI, United States

INTRODUCTION: HIV-associated neurocognitive disorders (HAND) remains a significant burden to persons living with HIV infection.^{1, 2} Introduction of antiretroviral therapy (ART) reduced the incidence of severe HIV dementia, yet the prevalence of milder forms of HAND continues to rise. Treatment also might change the presence and correlation of immunological markers with disease progression and severity.^{3, 4} To gain a better understanding of the relationship between neuroinflammation and neurochemical changes underlying the development of HAND, we combined localized *in vivo* proton magnetic resonance spectroscopy (¹H MRS) in selected brain regions with measurements of inflammatory cytokines in the cerebrospinal fluid (CSF) by a multiplex microsphere-bead based Immunoassay (MBIA) using the LUMINEX platform.

METHODS: Twenty-seven HIV subjects [14 with cognitive impairment (HIV+CI), age: 46.2± 8.6 years, education: 13.1± 1.9 years, global cognitive deficit score (GCS): -1.1± 0.38; 7 Asymptomatic, 6 with mild and 1 with moderate dementia), 13 with no cognitive impairment (HIV+NI, age 43.2± 8.5 years, education: 13.84± 2.0 years, GCS: 0.14 ± 0.33)] and 7 HIV-seronegative healthy controls (SN: aged:45.9± 9.9 years, education: 13.6±1.4 years, GCS: 0.36± 0.41) were each evaluated with detailed neuropsychiatric assessments, including lumbar punctures, neuropsychological tests, and ¹H MRS. Localized ¹H MRS was performed on a 3 Tesla Siemens Trio MR scanner in four brain regions: medial frontal gray matter (FGM), right frontal white matter (FWM), medial parietal grey matter (PGM) and right basal ganglia (BG) using a Point RESolved Spectroscopy (PRESS) acquisition sequence (TR/TE=3000/30ms, 64 averages, 3.5 min per location). LCModel analysis in conjunction with additional water T2 measurements allowed for determination of metabolite concentrations^{5, 6}. Interleukin -8 (IL-8) was measured by MILLIPLEX cytokine array (Millipore, Billerica, USA) on a Luminex 200 machine (Biorad, Hercules, USA).

RESULTS: **MBIA:** Elevated CSF IL-8 was observed in HIV+CI subjects (22.3 ± 6.5 pg/ml) compared to the SN controls (15.4± 4.2 pg/ml p= 0.021), or to HIV+NI (17.3± 8.5 pg/ml p= 0.099) (Figure 1). No difference was observed between HIV+NI subjects and SN controls. **MRS:** Myo-inositol (ml), a glial marker, showed trends to be elevated in HIV+CI subjects in all brain areas except the basal ganglia. The parietal grey matter showed the largest difference between HIV+CI (4.6 ± 0.4 millimol/kg) and SN controls (4.2 ± 0.6 millimol/kg, p=0.086) (Figure 2). In addition, CSF IL-8 correlated with ml in the parietal grey matter of the HIV-CI group (r= 0.565, p= 0.035) (Figure 3). No correlation was found in other brain regions.

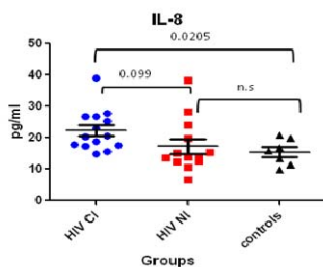


Figure 1. CSF IL-8 levels in three subject groups (mean±S.D.)

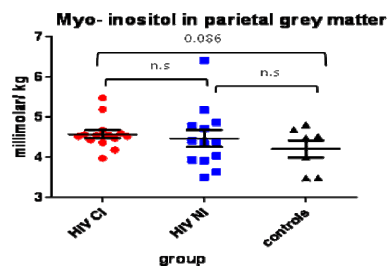


Figure 2. Myo-inositol in parietal grey matter in three groups (mean±S.D.)

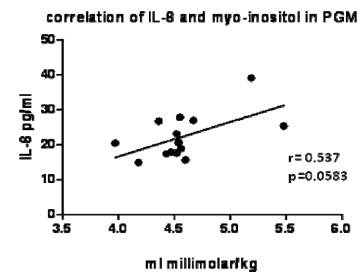


Figure 3. CSF IL-8 correlates with brain myo-inositol in HIV+CI subjects.

DISCUSSION: Elevated levels of CSF IL-8 in HIV+CI, as well as elevated brain ml on MRS in HIV subjects, are consistent with prior reports that evaluated these markers separately.^{7, 8} Here, we show a direct relationship between CSF IL-8 (a proinflammatory cytokine) and brain ml (a putative glial marker), since CSF IL-8 is released by microglia as well as astrocytes upon stimulation by other cytokines such as TNF α or by HIV infection as well as HIV derived proteins (e.g. TAT).^{7, 9, 10} Both markers seem to be upregulated in HIV+CI, implicating an ongoing immune response underlying this process. These findings demonstrate that ml is indeed a marker for both astroglial and microglia activation. Combined measurements of IL-8 and ml may provide surrogate markers for prognosis and disease progression of patients with HAND.

ACKNOWLEDGMENTS: Study supported by the NIH (1R01MH61427; K24DA16170; K02DA16991 & 1U54NS56883). We also thank R. Yakupov and R. Kitamura for data collection

REFERENCES: 1. Antinori A, et al. *Neurology* 2007; 69:1789-99; 2. Boisse L, et al. *Neurol Clin* 2008;26:799-819 ; 3. McArthur JC, et al. *Arch Neurol* 2006;61:1687-96; 4. Sevigny JJ, et al. *Neurology* 2004;63:2084-90; 5. Provencher SW *NMR Biomed* 2001;14:260-4; 6. Ernst T *J Magn Reson* 1993;102:1-8; 7. Zheng JC, et al. *J Neuroimmunol* 2008;200:100-10; 8. Chang L, et al. *Neuroimage* 2004;23:1336-47; 9. Kutsch O, et al. *J Virol* 2000;74:9214-21; 10. Sopper S, et al. *Virology* 1996; 220:320-9.