

# A DTI ANALYSIS OF LIMBIC SYSTEM STRUCTURAL INTEGRITY AND GLOBAL COGNITIVE STATUS IN PARKINSON'S DISEASE

T. R. Melzer<sup>1,2</sup>, R. Watts<sup>1,3</sup>, M. R. MacAskill<sup>1,2</sup>, R. Keenan<sup>4</sup>, C. Graham<sup>1,2</sup>, L. Livingston<sup>1,2</sup>, J. C. Dalrymple-Alford<sup>1,3</sup>, and T. J. Anderson<sup>1,2</sup>

<sup>1</sup>Van der Veer Institute, Christchurch, New Zealand, <sup>2</sup>University of Otago, Christchurch, New Zealand, <sup>3</sup>University of Canterbury, Christchurch, New Zealand, <sup>4</sup>Christchurch Radiology Group, Christchurch, New Zealand

**Aim:** To investigate diffusion MRI measures in key components of the limbic system as potential biomarkers in the progression of cognitive decline in Parkinson's disease (PD).

**Methods:** Thirty Parkinson's disease patients (mean age:  $69.4 \pm 7$  years) and 20 matched controls (mean age:  $71.0 \pm 7$  years) completed neuropsychological examination including the Montreal Cognitive Assessment (MoCA). The PD patients were categorized into cognitively intact (PDU,  $n = 9$ ), mild cognitive impairment (MCI,  $n = 9$ ), and dementing (PDD,  $n = 12$ ). Diffusion Tensor Imaging (DTI) data was acquired on a 3T GE HDx scanner using a diffusion-weighted spin echo EPI sequence ( $TE=75.5\text{ms}$  and  $TR=13\text{s}$ ) with diffusion weighting in 28 uniformly distributed directions ( $b=1000\text{s/mm}^2$ ) and four acquisitions without diffusion weighting. In-house software fit a tensor to motion corrected volumes and created Mean Diffusivity (MD) and Fractional Anisotropy (FA) maps for each participant. These images were normalized to the Montreal National Institute template using SPM5. Region-of-interest (ROI) analysis was used to investigate structural changes in key components of the limbic system, including limbic thalamus (t), basal forebrain/septal region (bs), hippocampus (h), parahippocampus (ph), amygdala (am), anterior cingulate (ac) and posterior cingulate (pc) (figure 1a). MD and FA values were assessed by one-way analysis of variance (ANOVA) followed by Tukey's HSD *post hoc* test; all comparisons with  $p < 0.05$  were considered significant. DTI measures were correlated with neuropsychological test scores in the PD patients.

**Results:** Of the 16 ANOVA tests (MD and FA from 7 regions plus total limbic system (ls)), five reached significance ( $0.0012 < p < 0.05$ ; MD: am, bs, ph; FA: bs, ph; figure 1b). *Post hoc* tests significantly differentiated between PDD and controls in the amygdala and parahippocampus and PDD and PDU in the basal forebrain/septal region. There were no significant differences among control, PDU, and MCI groups. Correlation analysis of MoCA and FA revealed significant results in t, am, bs, ph, and ls ( $0.38 < r < 0.60$ ) while MoCA and MD showed significant correlations in t, ac, bs, h, ph, and ls ( $-0.764 < r < -0.416$ ). See figure 1c.

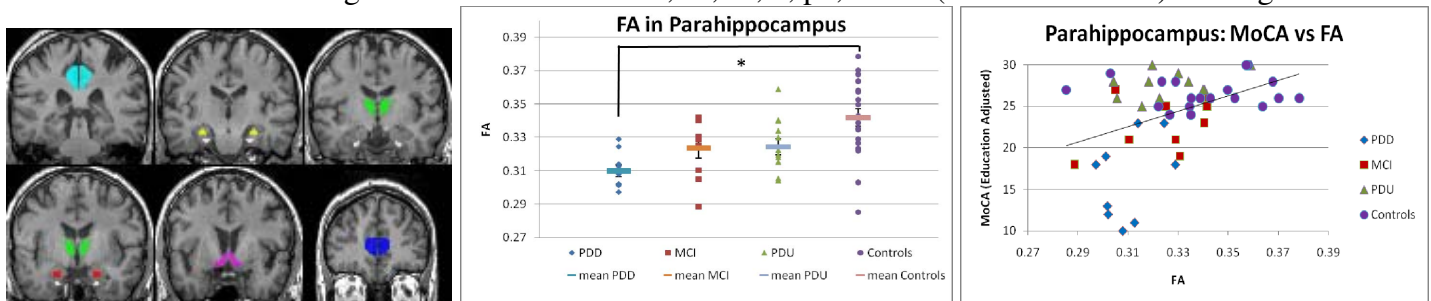


Figure 1: a.) The limbic system regions: Cyan-Posterior Cingulate; Yellow-Hippocampus; White-Parahippocampus; Green-Limbic Thalamus; Red-Amygdala; Pink-Basal Forebrain/Septal Region; Blue-Anterior Cingulate. b.) The spread and mean values for FA in the parahippocampus for each group. ANOVA resulted in  $F = 6.25$ ,  $p = 0.001$ . *Post hoc* tests revealed significant differences between PDD and Controls ( $*p = 0.03$ ). c.) Significant correlation between MoCA and FA in parahippocampus ( $r = 0.379$ ,  $p = 0.007$ ).

**Discussion:** These results show that PDU and MCI groups resemble controls more closely than PDD. Although *post hoc* testing identified no significant differences between controls, PDU, and MCI, a generalized monotonic trend emerged in both MD and FA measures. FA measures decreased steadily from controls to PDU to MCI and reached their lowest values in the PDD group. MD values increased from controls to PDD.

**Conclusion:** DTI measures from key limbic system structures successfully differentiated PDD from the other PD groups and controls and demonstrated a general trend of decline from cognitively intact PD patients through MCI to dementia. Furthermore, DTI measures within these structures correlated with cognitive measures. Thus DTI MRI is a promising method to evaluate and potentially track anatomical substrates of cognitive decline in Parkinson's disease.