

Direct Visualization of β -Amyloid Plaques in Alzheimer's Disease Brain Tissue Using Clinical Field Strength MRI

H. H. Kitzler¹, J. A. Ronald¹, Y. Chen¹, R. R. Hammond², and B. K. Rutt¹

¹Robarts Research Institute, University of Western Ontario, London, Ontario, Canada, ²Department of Neuropathology, University of Western Ontario, London, Ontario, Canada

Abstract:

Neuroimaging plays an important supportive role in the clinical diagnosis of Alzheimer's Disease (AD). However there are no human *in vivo* magnetic resonance (MR) imaging techniques that specifically demonstrate the formation of β -amyloid plaques (one of the histopathological hallmarks of AD) and no non-invasive imaging method exists that is able to diagnose AD reliably. High field strength, high resolution MR studies of excised human specimens [1] and *in vivo* AD animal model brain tissue [2] have shown intriguing evidence that MR can detect β -amyloid plaques on the basis of iron co-localization with these plaques [3]. There is now an urgent need for transitional research to develop and validate more clinically-relevant MR techniques that might still permit *in vivo* MR detection of individual β -amyloid plaques in AD patients.

Purpose:

The aim of this study was to adapt and exploit the highly SNR-efficient and iron-sensitive *Fast Imaging Employing Steady State Acquisition* (FIESTA) MR imaging, now well established from our single-cell MR work [4], for the detection of AD β -amyloid plaques at 3T. 3D FIESTA features an outstanding soft tissue contrast and has been successfully applied to several diagnostic tasks in clinical imaging. Our hypothesis was that individual β -amyloid plaques could be detected in human AD brain specimens, using the common clinical field strength of 3T and an optimized form of the FIESTA pulse sequence. We exploited a specialized gradient insert [5] in order to provide the spatial resolution needed for high-resolution imaging of isolated human brain tissue specimens.


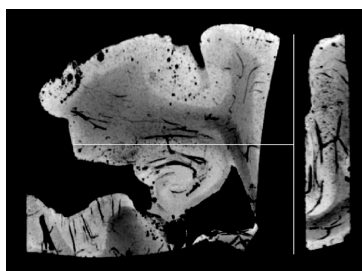


Fig.1) Human hippocampus and entorhinal cortex specimen featuring multiple focal signal voids with enlarged hippocampal insert of Bielschowsky's stain for plaques and neurofibrillary tangles. Part of the region is further enlarged and shown as a section of the β -A4 amyloid immunohistochemistry stain and the corresponding FIESTA detail. The pattern of the plaques can be recognized in the MR data. [image order from left to right].

Method:

MRI was performed on a 3T scanner (GE Signa HD) interfaced with an insertable gradient coil [peak strength: 500 mT/m, max peak slew rate: 3200 T/m/s] and 2cm diameter solenoidal RF coil. Isotropic FIESTA images of autopsy AD brain tissue (Braak&Braak VI; CERAD definite AD) were acquired in 218 minutes [(100 μ m)³; TR/TE 21/11 ms; FA 20°; BW \pm 8 kHz; phase cycling number/recon: 8/sum-of-squares]. FIESTA datasets were analyzed for the presence of focal signal voids [Fig.2]. Subsequent histological sections were stained for AD plaques and neurofibrillary tangles using Bielschowsky's and for β -amyloid protein using the β -A4-test immunohistochemical staining.



Result:

High-resolution 3DFIESTA imaging revealed spherical signal voids throughout the brain specimen parenchyma. Using a Minimum Intensity Projection (MinIP) technique, tubular intravascular signal voids could be distinguished from spherical intra-parenchymal signal losses [Fig.2]. The latter correlated to plaques in matched histological and IHC sections stained for β -amyloid plaques in the hippocampus and entorhinal cortex [Fig.1]. We observed correlations between patterns found in MRI and the histological images [Fig.1].

Fig.2) Minimum Intensity Projection (MinIP) of an isotropic tissue slab bearing different signal void structures of tubular and spherical configuration. The right lateral insert demonstrates a coronal cross section.

Discussion and Conclusion:

Our group has recently shown the feasibility of direct 3T MRI visualization of amyloid plaques in a novel rabbit model of AD [6]. In contrast to animal models, post-mortem formalin perfusion is not feasible in humans. Consequently human AD brain tissue specimens feature intravascular blood products caused by perimortal stasis. Those blood products give rise to a second paramagnetic intraparenchymal deposition that complicates the task of β -amyloid plaque detection; however, by shape analysis, voids due to β -amyloid plaques can clearly be discriminated from those arising from blood vessels [Fig.2]. Although our gradient insert permits gradient amplitudes and slew rates that are presently not available for human *in vivo* studies with clinical MR systems, this study nonetheless provides important evidence that clinical field strength MR has the intrinsic ability to detect microscopic iron associated with human β -amyloid plaques. Our *ex-vivo* MR imaging technique provides an important translationally-relevant tool for further specific cross-sectional analyses of AD brain.

References:

- | | |
|---|--|
| [1] Benveniste, H. et al. PNAS, 1999 | [2] Jack, C. et al. J of Neurosci, 2005 |
| [3] Falangola, M.F. et al. Neurochem Res 2006 | [4] Chronik, B. et al. MAGMA, 2000 |
| [5] Heyn, C. et al. MRM, 2006 | [6] Ronald, J. et al. Brain, 2008, submitted |