

Diffusion tensor imaging supports the cytotoxic origin of brain edema in experimental hepatic encephalopathy

L. Chavarria¹, M. Oria¹, J. Alonso², J. Córdoba¹, and S. Lope-Piedrafita³

¹Liver Unit, CIBEREHD, Hospital Vall Hebron, Barcelona, Spain, ²Magnetic Resonance Unit, CIBEREHD, Hospital Vall Hebron, Barcelona, Spain, ³Servicio de Resonancia Magnética Nuclear, CIBER-BBN, Universidad Autónoma de Barcelona, Cerdanyola del Valles, Barcelona, Spain

Introduction: Hepatic encephalopathy (HE) is a metabolic encephalopathy secondary to the effects of hepatic failure on central nervous system. HE is presumed to be caused by brain ammonium accumulation, because the liver is the main organ of ammonium disposal via urea cycle metabolism. Magnetic resonance has detected several abnormalities in patients with HE that support the development of brain edema secondary to the metabolism of ammonia to glutamine in astrocytes. Reproduction of these abnormalities in animal models will be very helpful to study the pathogenesis of HE.

Aim: Study water signal decay and spectra of brain tissue in an animal model of HE.

Methods:

Model of HE: Acute liver failure (ALF) was induced in Sprague-Dawley male rats (250-300g) by portocaval anastomosis and hepatic artery ligation. This model is characterized by highly predictable course: the precoma stage is defined as loss of the righting reflex and coma stage as loss of corneal reflex. Animals were anesthetized with isoflurane and body temperature was kept constant at $37 \pm 0.5^\circ\text{C}$. ALF rats ($n=6$) were assessed at 6 hours after hepatic artery ligation (6h), precoma stage (PC) and coma stage (Coma). Sham rats ($n=6$) were scanned following MRI of the ALF rats.

Magnetic resonance (MR): was performed in a Bruker BioSpec 70/30 USR at 7T to obtain T2 maps, using MSME sequence ($\text{TE}=10\text{-}120\text{ ms}$, $\text{TR}=2\text{ s}$) and diffusion tensor images (DTI) with EPI sequence ($\text{TR}/\text{TE}_{\text{eff}}=2\text{s}/35\text{ms}$, Δ/δ $20\text{ms}/4\text{ms}$). Diffusion images were acquired without ($b = 0\text{ s/mm}^2$) and with three b-values between $200\text{-}1000\text{ s/mm}^2$ along 20 diffusion directions. ADC maps were generated, as the diffusion tensor trace, using standard algorithm of Paravision[®] 4.0 software. Identical geometry was chosen for direct correlation between T2 and ADC maps (13 slices with 1 mm thickness, $\text{FOV}=35 \times 35\text{mm}^2$, $\text{matrix}=128 \times 128$). *In vivo* 1H-NMR spectra was done in rat brain using point-resolved spatially spectroscopy sequence, in $6.5 \times 6.5 \times 6.5\text{ mm}^3$ voxel with parameters: 4000Hz , TR/TE $2.5\text{s}/12\text{ms}$ with 64 scans. The regions of brain studied were motor cortex, sensorial cortex, thalamus, hypothalamus, hippocampus, striatum and globus pallidus.

Results: The spectra of ALF rat brains showed a progressive decrease of myoinositol (mlns) and an increase in glutamine (gln) in relation to the progression to coma. In addition, lactate (Lac) was markedly increased at coma stage (Fig. 1). Interestingly, ALF rats showed a decrease in diffusivity (ADC) compared to sham rats in all brains regions (Fig. 2 shows data from the motor cortex region). Moreover, ADC decreased during the progression of HE. However, no changes were found in T2 maps between sham and ALF rats.

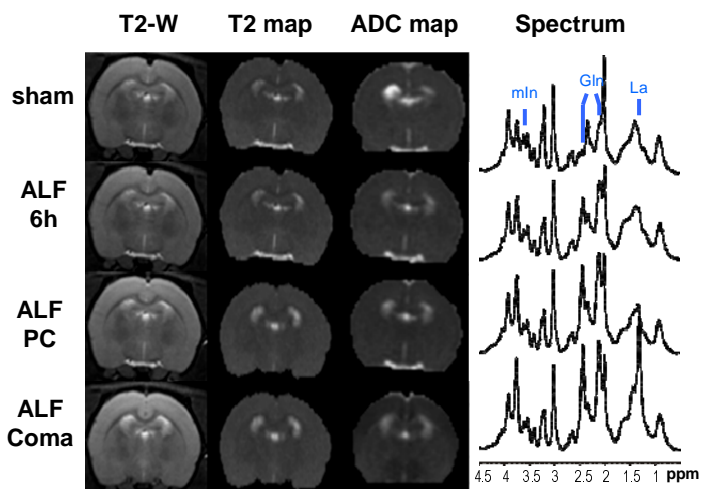


Fig. 1: T2-weighted images, T2 maps, ADC maps and 1H spectra of sham and ALF rat brains at 6 hours after hepatic artery ligation (ALF 6h), at precoma (ALF PC), and Coma stages.

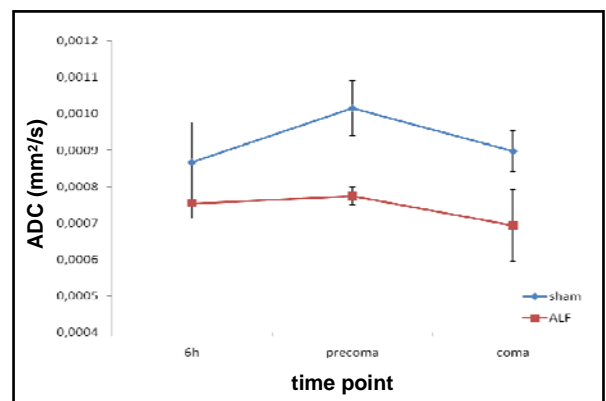


Fig. 2: ADC values in the motor cortex at three time points (6h, precoma, and coma). Sham (blue) and ALF (red). Significant differences found between sham and ALF at the three time points, and also between ALF 6 h and ALF precoma, and between ALF 6 h and ALF coma.

Conclusion: Magnetic resonance detects an increase in mean diffusivity in an experimental model of HE that is compatible with the development of cytotoxic brain oedema (astrocytic swelling). This abnormality is already present at early stages (6 hours) and precedes the development of neurological manifestations and is accompanied by changes in brain osmolytes: an increase in glutamine due to ammonium accumulation and a decrease in myo-inositol to compensate for it. At the latest stage rats develop coma and an increase in lactate, sign of anaerobic metabolism activation.