

## **<sup>1</sup>H MRSI Detection of Elevated Total Creatine in Brain Cancer: A Cautionary Tale**

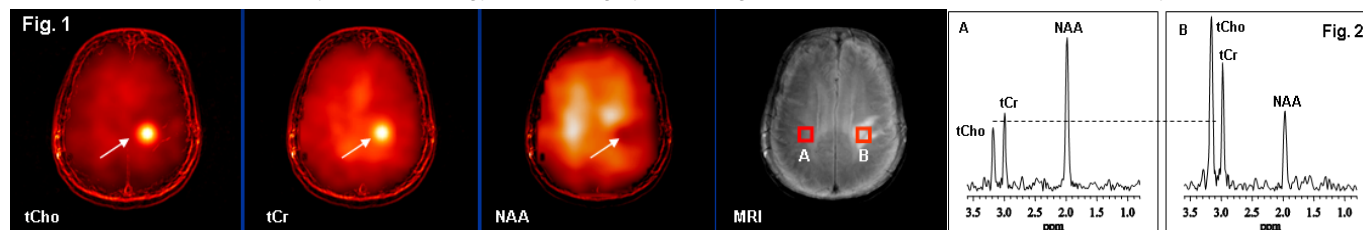
D. C. Shungu<sup>1</sup>, X. Mao<sup>1</sup>, A. J. Tsiouris<sup>1</sup>, C. E. Johnson<sup>1</sup>, J. P. Dyke<sup>1</sup>, L. A. Heier<sup>1</sup>, J. O. Comunale<sup>1</sup>, J. A. Boockvar<sup>2</sup>, and S. C. Pannullo<sup>2</sup>

<sup>1</sup>Radiology, Weill Cornell Medical College, New York, NY, United States, <sup>2</sup>Neurological Surgery, Weill Cornell Medical College, New York, NY, United States

**Purpose:** To report *three* clear-cut cases of MRS detection of dramatic elevations of total creatine (tCr, i.e., Cr + PCr) in brain tumors, which add incontrovertible evidence to the growing body of literature data<sup>[1,2]</sup> that has challenged the validity of the common practice of reporting metabolite levels as ratios to tCr, under the assumption that the integrated area of the tCr resonance remains constant as a result of the creatine phosphokinase-catalyzed interconversion of Cr and PCr.

**Methods:** Three patients with focal contrast-enhancing intracranial lesions were referred for examination by multislice <sup>1</sup>H MRSI to rule out multiple sclerosis, cerebral infarction or a brain neoplasm. The <sup>1</sup>H MRSI data were recorded on a GE 3.0 T MR system using the slice-interleaved method of Duyn et al<sup>[3]</sup>, with TE/TR 280/2300 ms, FOV 240 mm, four 15-mm slices and 3.5-mm gaps, 512 sample points, 32x32 circularly-stepped phase-encoding gradients, and a 2.5-kHz spectral width. Following post-processing, the resulting spectral data were interpreted by comparing metabolite levels in the lesions with those in the normal-appearing contralateral hemisphere, as well as with the results of the histopathologic analysis of the biopsy of two of the lesions.

**Results and Discussion:** Figure 1 presents metabolite images for one of the three cases to be reported, which were characterized by very large increases of tCho and tCr, and a decrease of NAA at the location of the lesion (see voxel [B] on the adjoining FLAIR image) compared to a similar location in the contralateral hemisphere (voxel [A]). The same data are shown spectrally in Fig. 2 for voxels from the lesion (2B) and contralateral side (2A). Note clear elevations of both tCho and tCr in the lesion, which was revealed by histopathology to be a highly cellular glial tumor composed of pleomorphic, hyperchromatic cells.



The final histopathology-based diagnosis for the lesions in two of the patients was glioblastoma multiforme (GBM). Although the pathology report for the third case is not yet available, it is very likely that it would turn out to also be a GBM, since it showed remarkably similar tCr, tCho and NAA changes.

**Conclusion:** While increased tCho concentration is now an established marker of cancer (see typical tCho “light bulb” in Fig. 1), our finding of clear cases of dramatic elevations of tCr (a tCr “light bulb”) in these brain lesions was unanticipated, and further urges caution in using the tCr spectral intensity as an internal concentration reference, especially in highly cellular, energized, and proliferating glial neoplasms.

**References:** [1] Frye MA, et al *Neuropsychopharm* 2007; **32**: 2490-2499. [2] Coplan JD, et al: *Psychiatry Res* 2006; **147**: 27-39. [3] Duyn JH, et al: *Radiology* 1993; **188**: 277-282.