

Tract-Based Spatial Statistics (TBSS) Study in Parkinson's Disease Identifies Focal Microstructural Abnormality

M. Ezra¹, V. Gontu², M. Abaei¹, P. S. Morgan¹, N. Bajaj², and D. P. Auer¹

¹Academic Radiology, University of Nottingham, Nottingham, United Kingdom, ²Neurology, Derby Royal Infirmary, Derby, United Kingdom

Introduction

Parkinson's disease (PD) is a degenerative disorder characterised primarily by pathological changes involving the loss of nigrostriatal dopaminergic neurons. In addition there are increasingly recognised deficits of non-motor cerebral domains such as those involved in cognition¹. As yet there has been little published quantifying the role white matter (WM) cerebral pathology plays in these higher deficits. It is the aim of this study to assess the integrity of the WM tracts in PwPD using DTI and a novel method of whole brain analysis Tract Based Spatial Statistics (TBSS)².

Subjects and Methods

We studied 24 PwPD and 16 age- & sex- matched healthy controls. All PwPD fulfilled Queens Square Brain Bank criteria for diagnosing PD. 11 were of the clinical subgroup of Postural Instability Gait Difficulty (PIGD) and 13 Tremor Dominant PD (TDPD). Patients with a Mini Mental State Exam Score of less than 26 were excluded. DTI and T2_w GRASE images were acquired on a Philips Achieva 3 T MR scanner for all subjects. Image processing was completed using FSL 4.1.0. Visual inspection led to the exclusion of 1 control, 4 PI GD and 4 TDPD. TBSS processing was performed as described by Smith². Constrained nonlinear registration to the FMRIB58_FA standard space was chosen. The white matter skeleton was threshold at FA ≥ 0.2 . Voxelwise statistics across subjects were performed using a univariate linear modelling approach, applying a general linear model (i.e., multiple regression) where $N = 5000$. Inference was carried out using Threshold Free Cluster Enhancement (TFCE). Two-regressor analyses were performed to test for significant differences between Controls/PIGD/TDPD. Covariate analysis was performed with acquired PD scores. Affected WM tracts were masked and Region of Interest (ROI) analysis of FA was performed and subjected to MANCOVA.

Results

Multiple areas were identified where reduction in WM FA in the PI GD vs. Controls reached significance ($p < 0.05$). These were all found in the left hemisphere and included the Posterior and Superior corona radiate, Posterior thalamic radiation (include optic radiation), Retrolenticular part of internal capsule and Superior longitudinal fasciculus (Fig. 1). These changes were not present in the other two-regressor analyses. Covariance analysis failed to demonstrate a significant correlation between WM FA and PD scores. ROI cross tract analysis of mean FA identified a group specific trend (Fig. 2), with a significant group difference (Wilks' Lambda $p = 0.04$). Bilateral moderate to marked leukoaraiosis was noted in 2 TDPD and 1 PI GD.

Discussion

Our analysis is the first to be successful in using DTI and TBSS to investigate the changes that occur in the WM of PwPD. We have demonstrated reduced Fractional Anisotropy (FA) in the WM preferentially in PwPIGD. Posthoc analysis identified a significant subgroup concordance. These changes were unrelated to Parkinson Severity Scales that mainly portray motor symptoms. Lack of correlation with Cognitive Scores, however is likely to reflect limited cognitive impairment of the study group. Nevertheless it is known that the PI GD subgroup is particularly prone to developing dementia³ In fact a recent study of PwPD with impaired executive function showed reduced left parietal WM FA⁴.

Conclusion

The tract specific findings located to the temporo-parietal association tracts & the subgroup concordance are consistent with a possible underlying mechanism of cognitive impairment PD.

References

- 1 Chaudhuri KR (2006) Lancet Neurol, 5:235–45.
- 2 Smith SM (2006) NeuroImage, 31:1487–1505
- 3 Verbaan D (2007) J. Neurol. Neurosurg. Psychiatry, 78:1182–1187
- 4 Matsui H (2007) Acta Neurol Scand, 116(2):108–12

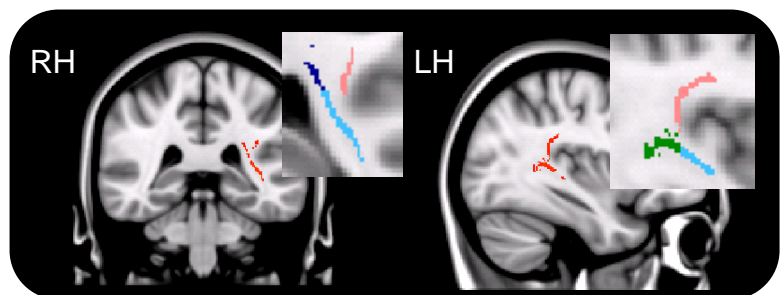


Fig. 1 Statistical maps showing voxels where FA was significantly decreased (Red) in PI GD compared to Controls at $p < 0.05$. Masks: Posterior and Superior corona radiate (Dark Blue), Posterior thalamic radiation (Green), Retrolenticular part of internal capsule (Light Blue) and Superior longitudinal fasciculus (Pink)

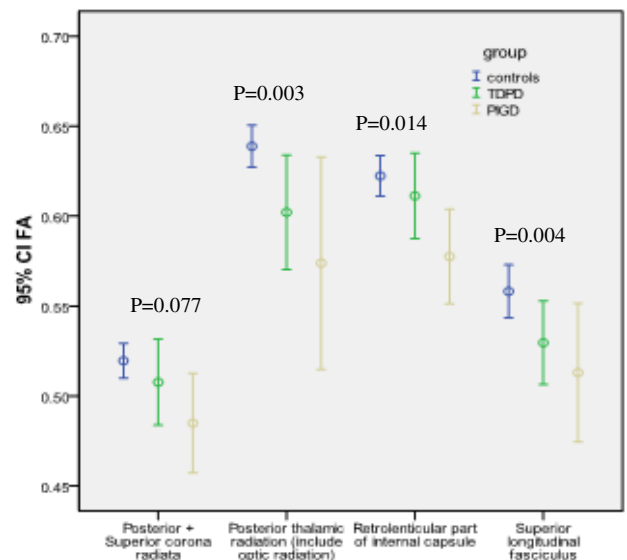


Fig. 2 Means and 95% Confidence intervals of mean FA values in each ROI (tract) across subgroups with Univariate Statistics (p value).