

# Aricept® Treatment Enhances Hippocampal Connectivity in Subjects with Mild Alzheimer's Disease

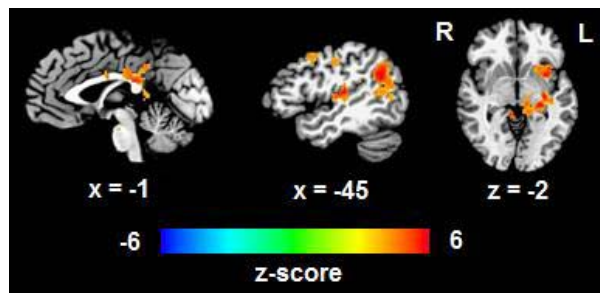
W. Li<sup>1</sup>, C. Xie<sup>1,2</sup>, Z. Wu<sup>1</sup>, J. Jones<sup>3</sup>, P. Antuono<sup>3</sup>, T. McRae<sup>4</sup>, and S.-J. Li<sup>1,5</sup>

<sup>1</sup>Biophysics, Medical College of Wisconsin, Milwaukee, WI, United States, <sup>2</sup>Neurology, School of Clinical Medicine, Southeast University, Nanjing, Jiangsu, China, People's Republic of, <sup>3</sup>Neurology, Medical College of Wisconsin, Milwaukee, WI, United States, <sup>4</sup>Pfizer, Inc., <sup>5</sup>Psychiatry, Medical College of Wisconsin, Milwaukee, WI, United States

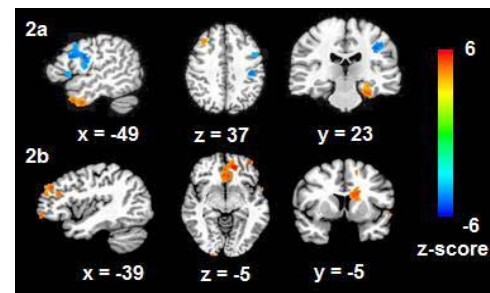
**Background:** Cholinergic inhibitor (Aricept®) has proven to be successful in improving the cognitive function of adults with Alzheimer's disease (AD) [1]. However, little is known about the neural correlates of the effects of Aricept® and cognitive improvement of AD study subjects. We hypothesize that since the cortical and hippocampal areas receive major cholinergic input from the basal forebrain nuclei, treatment with Aricept® can improve the cholinergic activity of AD [2]; it will improve connectivity of the hippocampus network. In the present study, we will determine the neural correlates between changes in the measures of cognitive improvement. To this end, we used the Mini Mental Status Examination (MMSE) scores and AD Assessment score (ADAS-cog). We examined changes in hippocampal functional connectivity before and after 3 months of Aricept® treatment in study subjects with mild AD.

**Methods:** A total of 14 patients (age  $77.57 \pm 6.57$  yrs) with newly diagnosed Alzheimer's disease (MMSE 23-26) were enrolled for a 3-month follow-up drug treatment study. Magnetic resonance images were taken before and after the patients took donepezil hydrochloride (Aricept®) treatment. **MRI protocol:** MRI scanning was performed on a GE 3T Signa LX scanner. High-resolution anatomical images were acquired using a 3D spoiled gradient echo (SPGR) sequence with 144 continuous axial slices. Six-minute resting-state functional MR images were obtained using a single-shot EPI sequence (TR/TE/FA/thickness/matrix size = 2s/25ms/90°/5mm/64x64) with 36 sagittal slices. **Data Analysis:** AFNI software was used to process the data. First, the hippocampus masks were obtained for each study subject using individual SPGR images. Then, we examined the functional connectivity between the hippocampus and the entire brain using the cross-correlation of the spontaneous low-frequency fluctuations in the resting-state fMRI. The nonparametric Wilcoxon signed-rank test was performed to determine the functional connectivity change across study subjects before and after the drug treatment. Finally, the linear regression was performed to identify the neural correlates between functional connectivity and ADAS-cog, MMSE scores for all subjects.

**Results and Discussion:** The hippocampus is a key region in the memory circuits; it plays an important role in information-encoding and retrieval. Following a 3-month treatment with Aricept®, we found that the hippocampal functional connectivity exhibited a significant increase in the left posterior cingulate cortex (PCC), bilateral dorsal lateral prefrontal cortex (DLPFC), left Supramarginal gyrus (SMG), left insula, left putamen, left parahippocampal gyrus, and bilateral middle frontal gyrus (MFG) (**Fig. 1**). Linear regression analysis showed a significant correlation between the hippocampal connectivity and the changes in MMSE scores in the bilateral DLPFC, left inferior frontal gyrus (IFG), left hippocampus, and left precentral cortex. Significant correlation between hippocampal connectivity and changes in ADAS-cog were found in the left anterior cingulate cortex (ACC), left caudate and left DLPFC (**Fig. 2**). These results suggest that the alteration of the functional connectivity pattern after the Aricept® treatment is closely associated with cognitive improvement. Therefore, the changes in HFC detected by fMRI analysis may serve as a surrogate marker to monitor and assess the therapeutic response to Aricept® treatment in patients with Alzheimer's disease.



**Fig. 1.** Increased hippocampal connectivity in the left posterior cingulate cortex (PCC), bilateral dorsal lateral prefrontal cortex (DLPFC), left Supramarginal gyrus (SMG), left insula, left putamen, left parahippocampal gyrus, and bilateral middle frontal gyrus (MFG) after the 3-month Aricept treatment.



**Fig. 2.** Linear Correlation maps between changes in hippocampus functional connectivity with  $\Delta$  MMSE score (a) and with  $\Delta$  ADAS-cog (b).

**References:** 1. Kircher TT et al. Am J Geriatr Psychiatry 2005, 2. Petersen RC et al. N Engl J Med 2005, 3. SJ Li et al. Radiology 2002.

**Acknowledgement:** This work was supported by the NIH grants AG20279 and Pfizer, Inc.