

# Relationship Between Brain R2 and Liver and Serum Iron Concentrations in Elderly Men

M. J. House<sup>1</sup>, T. St. Pierre<sup>1</sup>, J. Olynyk<sup>2</sup>, E. Milward<sup>3</sup>, and D. Bruce<sup>2</sup>

<sup>1</sup>School of Physics, The University of Western Australia, Crawley, Western Australia, Australia, <sup>2</sup>School of Medicine and Pharmacology, The University of Western Australia, Crawley, Western Australia, Australia, <sup>3</sup>School of Biomedical Sciences, The University of Newcastle, Newcastle, New South Wales, Australia

## Introduction

Studies of iron overload in humans and animals suggest that brain iron is affected in a regionally specific way by changes in body iron status. We hypothesise that brain iron in healthy adults is also affected by changes in body iron status. To test our hypothesis we used MRI to measure the proton transverse relaxation rate ( $R_2$ ) in 14 grey and white matter brain regions in twenty healthy elderly men (average age 76.1 years).

## Methods

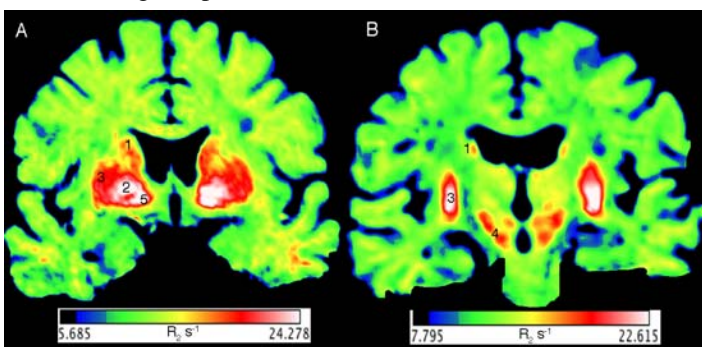
All MRI measurements were made on a 1.5T Siemens Avanto whole body scanner. For the brain scan, coronal images parallel to the brain stem were acquired with a multislice (20 slices) single spin-echo (SSE) pulse sequence with TR/TE (2500/17, 30, 45, 60, 90 ms). FerriScan® (1,2) MRI data were acquired for the measurement of liver iron concentration (LIC) during the same session as the brain scan. Axial images of the abdomen were acquired with a multislice (11 slices) single spin-echo pulse sequence with TR/TE (2500/6, 9, 12, 15, 18 ms). The transverse relaxation rate,  $R_2$ , was calculated by curve fitting each voxel signal intensity datum for all echo times to monoexponential (brain) or biexponential (liver) spin echo signal intensity equations. The average  $R_2$  value of each brain region was acquired following the methodology of House et al. (3). Brain  $R_2$  values (Figure 1) were compared to LIC measured using the Ferriscan® MRI technique and serum iron indices (iron, ferritin, transferrin, transferrin saturation) acquired at the time of the MRI scan (time point 2) and three years before the current study (baseline). Correlations between brain  $R_2$  values and body iron indices were assessed with Spearman's rank correlation coefficient.

## Results

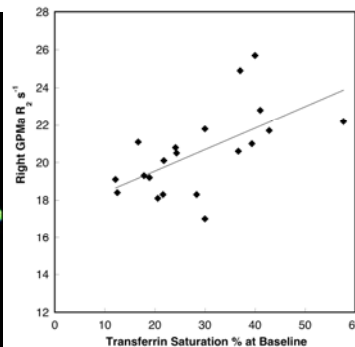
Post-mortem iron concentrations from the literature (4) were strongly correlated with mean  $R_2$  values from five brain regions ( $r = 0.99$ ,  $p = 0.0008$ ).  $R_2$  values in the medial globus pallidus were significantly correlated with LIC (left hemisphere  $r = 0.669$ ,  $p = 0.0013$ ; right hemisphere  $r = 0.617$ ,  $p = 0.0038$ ), baseline serum iron concentrations (left hemisphere  $r = 0.611$ ,  $p = 0.0042$ ), and baseline transferrin saturation (left hemisphere  $r = 0.563$ ,  $p = 0.0097$ ; right hemisphere  $r = 0.637$ ,  $p = 0.0025$ ) (Figure 2).  $R_2$  values in the right ventral pallidum were significantly correlated with LIC ( $r = 0.622$ ,  $p = 0.0059$ ) (Figure 3). There was a significant negative correlation between brain  $R_2$  values in the left corpus callosum and transferrin saturation measured at time point two ( $r = -0.62$ ,  $p = 0.0035$ ). There were no significant correlations between brain  $R_2$  values and serum ferritin concentrations at either time point. In general, grey and white matter regions showed opposing correlations with body iron status.

## Conclusions

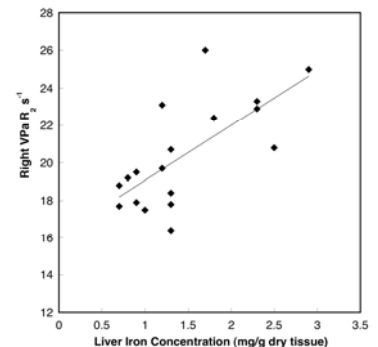
Our results suggest that iron levels in specific grey matter brain regions are linked to the systemic iron status in elderly men. Liver iron concentrations, in particular, appear to show the strongest association with  $R_2$  values in the brain. The trends we observed in grey and white matter suggest that the response of the elderly male brain to higher iron concentrations in peripheral organs is not uniform and is tissue and region specific.



**Figure 1**  $R_2$  images of the anterior (A) and posterior (B) slices for one participant acquired in this study. The hot colours (white, red) show the areas with the highest  $R_2$  values. Intermediate  $R_2$  values are yellow to green and the lowest  $R_2$  values are blue. The highest  $R_2$  values generally coincide with brain regions high in iron like the caudate nucleus (1), globus pallidus (2), putamen (3), substantia nigra (4), and ventral pallidum (5).



**Figure 2** Plot of  $R_2$  in the right medial globus pallidus versus serum transferrin saturation at baseline.



**Figure 3** Plot of  $R_2$  in the right ventral pallidum versus liver iron concentration.

## References

- 1) St Pierre TG, Clark PR, Chua-Anusorn W. Single spin-echo proton transverse relaxometry of iron-loaded liver. *NMR Biomed* 2004;17(7):446-458.
- 2) St Pierre TG, Clark PR, Chua-Anusorn W, Fleming AJ, Jeffrey GP, Olynyk JK, Pootrakul P, Robins E, Lindeman R. Noninvasive measurement and imaging of liver iron concentrations using proton magnetic resonance. *Blood* 2005;105(2):855-861.
- 3) House MJ, St Pierre TG, Foster JK, Martins RN, Clarnette R. Quantitative MR Imaging  $R_2$  relaxometry in elderly participants reporting memory loss. *AJNR* 2006;27(2):430-439.
- 4) Hallgren B, Sourander P. The effect of age on the non-haemin iron in the human body. *J Neurochem* 1958;3:41-51.