

Differentiation of pancreas carcinoma from healthy pancreatic tissue using a wide range of b-values: Comparison of ADC and IVIM parameters

A. Lemke¹, L. R. Schad¹, F. Laun², and B. Stieltjes³

¹Chair in Computer Assisted Clinical Medicine, University of Heidelberg, Faculty of Medicine, Mannheim, Germany, ²Department of Medical Physics in Radiology, German Cancer Research Center, Heidelberg, Germany, ³Department of Radiology, German Cancer Research Center, Heidelberg, Germany

Introduction:

Diffusion-weighted Imaging (DWI) and the derived apparent diffusion coefficient (ADC), has been reported to differentiate pancreatic cancer from healthy pancreatic tissue [1, 2]. Although the separation between diffusion and microperfusion has been discussed [3, 4], no reports for the pancreas have been published investigating this separation in detail. In this study we perform DWI with a wide range of b -values to determine changes of diffusion and microperfusion in healthy pancreatic tissue and pancreatic cancer.

Materials and Methods:

Six healthy volunteers and six patients with histologically proven pancreatic carcinoma were measured at 1.5 Tesla (Magnetom Avanto, Siemens Medical Solutions, Erlangen). Axial DWI was performed using a single-shot echo-planar imaging (SE-EPI) pulse sequence in expirational breath-hold: TR/TE = 1300/60 ms, 14 slices, SL = 5 mm, matrix size = 100x82 with a 3.5 mm pixel resolution, 4 averages, bandwidth = 3000 Hz/pixel and a total measurement time of 12 minutes. The acquisition was separated into 10 blocks (b_0, b_{25}), (b_0, b_{50})...(b_0, b_{800}) and each block was acquired in a single breath-hold (TA = 26 ms) to avoid motion artefacts. Anatomical scans included an axial T_{1w}-pace triggered T_{1w} (TR/TE = 102/4.8 ms, SL = 4 mm) spin echo sequence. Images were post processed using mono exponential fitting applying a) all b -values, yielding ADC₀₋₈₀₀ and b) the 5 lowest b -values, yielding ADC₀₋₁₅₀. Regions of interest (ROI) were placed in healthy pancreas parenchyma and in tumor tissue to calculate the signal intensity for all b -values. Using the biexponential IVIM-approach [3], the perfusion fraction f , the pseudo diffusion coefficient D^* and the diffusion coefficient D were extracted for all participants. A pair wise Mann-Whitney U-test was used to test for statistically significant differences between the patients and the healthy volunteers.

Results:

Figure 1 shows a single slice of a patient with pancreas carcinoma. It demonstrates the image quality of the DW-data and the improved delineation of the tumor on the ADC-map using lower b -values. The signal decay as a function of b in pancreatic cancer is markedly lower than in the healthy pancreas at low b -values, as shown exemplarily in figure 2. In tumor tissue the signal decay is monoexponential and in healthy tissue it is biexponential. This leads to a lower perfusion fraction f in the biexponential fit. The superiority of this parameter to distinguish pancreatic tumor from healthy tissue is shown in table 1, where the measured parameters were calculated from the patients with pancreatic cancer and healthy volunteers. In contrast, the difference in the diffusion coefficient D does not reach significance. The large standard deviation of the pseudo diffusion coefficient D^* in tumor tissue arises from overfitting the monoexponential signal decay to a biexponential model and is therefore not useful. The significance level p also shows that ADC₀₋₁₅₀ is more sensitive to differences than ADC₀₋₈₀₀.

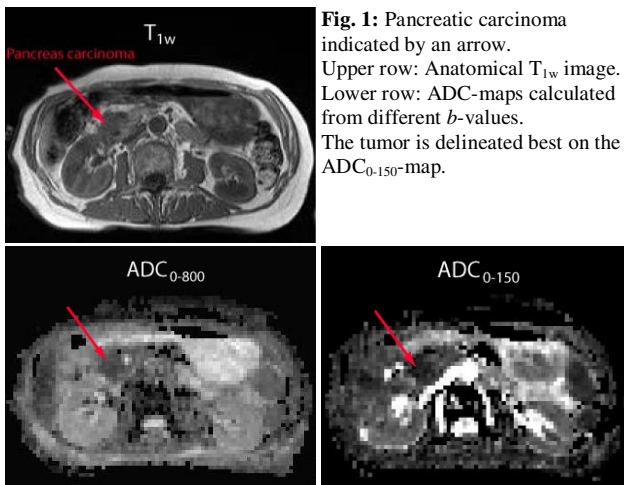


Fig. 1: Pancreatic carcinoma indicated by an arrow. Upper row: Anatomical T_{1w} image. Lower row: ADC-maps calculated from different b -values. The tumor is delineated best on the ADC₀₋₁₅₀-map.

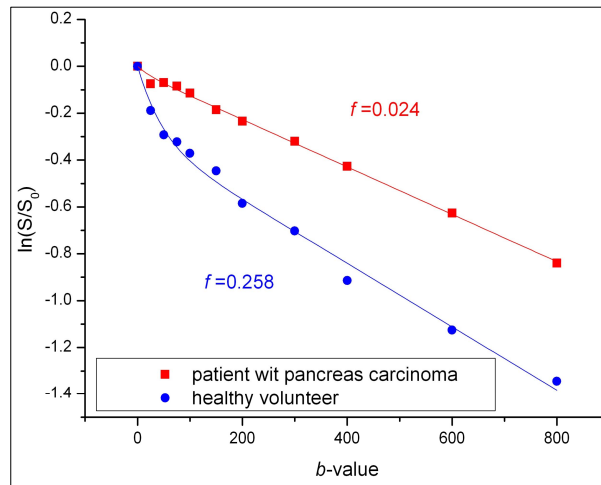


Fig. 2: Biexponential fit of the DW signal decay as a function of b in tumor and healthy tissue in the pancreas. The perfusion fraction f and therefore the biexponential behavior are markedly lower in the tumor tissue compared to the healthy tissue.

	f	D in 10^{-3} mm ² /s	D^* in 10^{-3} mm ² /s	ADC ₀₋₁₅₀ 10^{-3} mm ² /s	ADC ₀₋₈₀₀ in 10^{-3} mm ² /s
pancreatic cancer	0.061±0.040	1.12±0.28	73.8±69.4	1.65±0.41	1.16±0.29
healthy pancreas	0.279±0.085	1.21±0.17	27.3±13.5	3.52±0.91	1.45±0.05
p-value	0.002	0.846	0.818	0.008	0.064

Tab. 1: Extracted parameters in the pancreas of the patient group and the healthy volunteers. The perfusion fraction f and the ADC₀₋₁₅₀ are significantly lower in the tumor compared to the healthy pancreas.

Discussion:

This study demonstrates that the well-known reduction in perfusion in pancreatic cancer is detectable using DWI with a wide range of b -values and the IVIM-model. In comparison to healthy tissue, this reduction in perfusion leads to a reduced signal decay at low b -values and thus to a significant decrease in the perfusion fraction f in pancreatic tumor. The perfusion fraction is a highly sensitive parameter to detect pancreatic cancer and is superior to the diffusion coefficient D and ADC.

References:

[1] Lee SS, J Magn Reson Imaging 2008;28(4):928-936
[3] Le Bihan D, Radiology 1988;168(2):497-505

[2] Matsuki M, Abdom Imaging 2007;32(4):481-483
[4] Mueller et al. Eur.J.Radiol. 26:297(1998)