

Evaluation of Diffusion-weighted MR imaging for Detection of Bowel Inflammation in Patients with Crohn's Disease: A Pilot Study

A. Oto¹, F. Zhu¹, K. Kulkarni¹, M. Hori¹, A. Kayhan¹, G. S. Karczmar¹, J. R. Turner², and D. Rubin³

¹Department of Radiology, The University of Chicago, Chicago, IL, United States, ²Department of Pathology, The University of Chicago, Chicago, IL, United States,

³Department of Medicine, The University of Chicago, Chicago, IL, United States

INTRODUCTION:

MR imaging has been increasingly used for the diagnosis and follow-up of patients with inflammatory bowel disease. Currently, evaluation of the bowel wall by MR imaging is based on its signal on T2-weighted images, thickness and the degree of contrast enhancement (1). While the results of MR imaging using these criteria are promising, several clinically important issues such as accurate estimation of the extent of disease, reliable differentiation between chronic and active inflammation and monitoring response to treatment remain as diagnostic challenges. Diffusion weighted imaging (DWI) reflects the changes in the water mobility caused by interactions with cell membranes, macromolecules and alterations of the tissue environment. To our knowledge, the use of DWI for the detection of bowel wall inflammation and its associated features has not been previously described.

The purposes of our study were to determine the possibility of a role for diffusion weighted MR imaging in detection of bowel inflammation and investigate the changes in apparent diffusion coefficient (ADC) values of the inflamed bowel in patients with Crohn's disease.

METHODS:

A total of 32 MR examinations were performed for suspected or known Crohn's disease during the specified time. Eleven patients (seven women, four men; mean age: 36.8; range, 21-74 years) who also had subsequent colonoscopy or bowel resection within 4 weeks of MR enterography were included in this retrospective study to have either endoscopy or pathology as the gold standard. Two patients had partial colectomy (one right hemicolectomy and one cecectomy) and ileal resection prior to MR enterography. The MRI examinations were performed with a 1.5-T GE Signa unit. Patients fasted for 6 hours before the MRI examination. 1350 ml of Volumen (E-Z-EM Inc) was administered orally to every patient over 45 minutes before the study. One milligram glucagon was administered intramuscularly when the patient was placed in the scanner, immediately before starting the examination. After acquiring a standard three-plane scout image, axial and/or coronal DWI images (b values of 0 and 600 s/mm², TR/TE 8000/75, matrix 128 x 128-224, slice thickness/gap: 7 mm/0mm, number of excitations:4) were obtained. The upper abdomen and pelvis were scanned separately. Field of view ranged between 32 and 40 cm and ASSET factor of 2 was used in all sequences.

The bowel was divided into six segments: terminal ileum, cecum, ascending colon, transverse colon, descending colon and rectosigmoid. DWI of the bowel was retrospectively evaluated by two radiologists who were blinded to the clinical and endoscopic examinations and surgery results. Each segment was graded for the presence of inflammation on a 4-point confidence scale based on wall thickening and wall signal on DWI and ADC map as follows: 0 = definitely absent (imperceptible wall, both in signal and thickness); 1 = probably absent (normal thickness, signal intensity and thickness are similar to the surrounding bowel segments); 2 = probably present (normal wall thickness but signal intensity is increased on DWI and decreased on ADC map); 3 = definitely present (thick bowel wall and signal intensity is increased on DWI and decreased on ADC map). Bowel wall was accepted to be thickened when it was > 3mm. Grading scores of 0 and 1 were regarded as indicating normal bowel wall and scores of 2 and 3 were regarded as indicating bowel wall inflammation on DWI.

ADC's were calculated for each bowel segment. ADC measurements were performed for each segment by two different radiologists who were blinded to the clinical, endoscopic and surgical results, on a workstation with commercially available diffusion analysis software. The measurements were made from the area of brightest signal in the bowel wall. ROI areas varied between 12-30 mm². The mean of the two ADC values was accepted as the ADC value of the segment.

The reports of endoscopic examinations, surgical procedures and pathology results were reviewed by a third radiologist who was not involved in the image analysis. Visualization of inflamed mucosa on endoscopy or evidence of bowel inflammation in the biopsy or resected surgical specimen was accepted as proof of inflammation and noted for each segment. Qualitative and quantitative DWI findings were compared with this clinical gold standard.

Sensitivity and specificity were calculated for qualitative inflammation score with pathologic findings of inflammation as gold standard. Receiver operating characteristic (ROC) curve was constructed for ADC values and the area under the ROC curve is a measure of the overall ability of discriminating inflamed and normal bowels.

RESULTS:

A total of 53 segments could be evaluated by endoscopy (n=31) or surgery (n=22). On the basis of these gold standard evaluations, 34 bowel segments were normal and 19 segments demonstrated inflammation.

Of the 34 normal bowel segments, DWI detected 28 correctly, yielding a specificity of 82.4%. However, 6 normal bowel segments in 4 patients were incorrectly characterized as inflamed by DWI. Of the 19 inflamed segments, DWI detected 18 correctly, yielding a sensitivity of 94.7%. Inflammation could not be detected in one segment.

The mean ADC values of proven inflamed bowels was $1.59 \pm 0.45 \times 10^{-3} \text{ mm}^2/\text{s}$ (range: 0.46 – 2.50), compared to $2.74 \pm 0.68 \times 10^{-3} \text{ mm}^2/\text{s}$ (range: 1.44 – 4.03) in normal bowel segments ($p < 0.0001$). The area under the ROC curve was 0.938 (95% confidence interval: 0.873 – 1.000) (Fig 1).

DISCUSSION:

Our study results indicate that inflammation of the bowel wall causes restricted diffusion and DWI yields both qualitative (increased signal intensity) and quantitative (decreased ADC value) information that can be helpful for evaluation of bowel inflammation. To our knowledge, DWI findings of bowel inflammation in patients with Crohn's disease were not previously published before. Further studies with larger populations are needed to support our findings and to better define the role of DWI in the clinical management of these patients.

REFERENCES:

1. Fidler J. MR imaging of the small bowel. Radiol Clin North Am. 2007; 45:317-331.

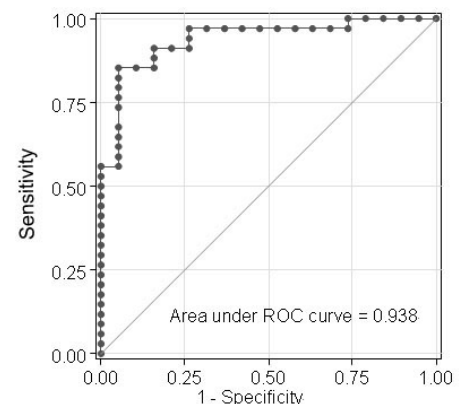


Figure 1. ROC curve for ADC value