

# White Matter is Diffusely Affected in Autism

A. L. Alexander<sup>1</sup>, J. Lee<sup>1</sup>, E. D. Bigler<sup>2</sup>, M. B. DuBray<sup>2</sup>, A. Froehlich<sup>2</sup>, N. Lange<sup>3</sup>, T. P. Fletcher<sup>2</sup>, M. K. Chung<sup>1</sup>, and J. E. Lainhart<sup>2</sup>

<sup>1</sup>University of Wisconsin, Madison, WI, United States, <sup>2</sup>University of Utah, Salt Lake City, UT, United States, <sup>3</sup>Laboratory for Statistical Neuroimaging McLean Hospital, Belmont, MA, United States

## Introduction

A neural basis of autism spectrum disorders remains elusive. One of the leading hypotheses is that the brain in autism exhibits an underconnectivity, particularly of long-range connections [1]. Several recent DTI studies have found abnormal white matter in autism [2-5], most consistently in the corpus callosum, but also in other brain regions. In this study, an advanced voxel-based analysis was performed using state-of-the-art methods including nonlinear co-registration, Fniirt-FSL, white matter segmentation, and correction of partial volume blurring effects with T-SPOON [6]. Tract-based spatial statistics (TBSS – FSL [7]) was also applied for comparison. These methods were applied to a cohort of 43 high-functioning subjects with autism and 34 typically developing controls matched for age, IQ, handedness and head circumference. Group comparisons were performed for FA, mean diffusivity (MD) and the three eigenvalues of the diffusion tensor (EV1, EV2 and EV3).

## Methods

**Data:** DTI data from 43 autism (mean age 16.27 years; S.D. 6.64) and 34 typically developing subjects (mean age 16.44 years; S.D. 5.97) were acquired using a single-shot spin echo EPI sequence (SENSE parallel imaging R=2) with diffusion-tensor encoding (12 directions, b=1000s/mm<sup>2</sup>, voxels = 2x2x2.5mm, 3 averages). The data were corrected for head motion, eddy currents static field inhomogeneities using a combination of AIR [8], FSL field map correction, and in-house software.

**TBSS:** TBSS analysis was done using FSL 4.1.0 described in Smith et al [7]. A nonlinear warp was performed using an option -T, which uses the FMRIB58\_FA\_1mm for the template.

**T-SPOON:** Using the same nonlinear warping transformation that was used for the TBSS above, white matter segmented mask, and DTI measurements (FA, MD, eigenvalues) were transformed and smoothed using Gaussian smoothing (FWHM 4mm) to create T-SPOON data.

**Statistics:** The voxel-wise statistical analysis was done using an FSL function 'randomise', which is a non-parametric permutation test. The random permutation number was chosen as 5000 for both skeleton data and T-SPOON whole brain data. Group difference results were investigated using TFCE [9] using optimization parameters (-T2 for the skeleton and -T for the whole brain data) and a threshold of corrected p value < 0.01

## Results

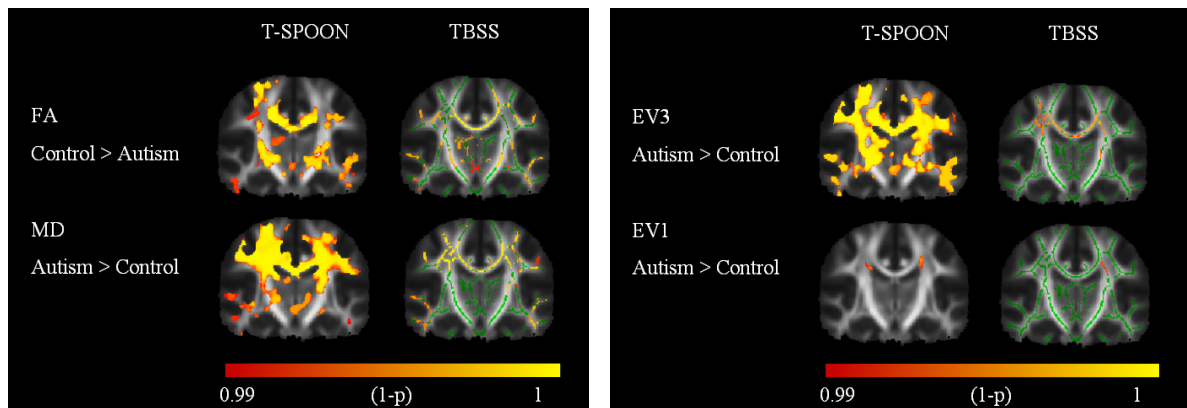
In general, the DTI group differences appear to be quite diffuse over much of the white matter. In particular, the corpus callosum shows consistent group differences across FA, MD, EV2 and EV3 (see Figure), which concurs with previously published DTI studies of autism [2-4]. **Fractional Anisotropy:** Group comparisons of FA showed significantly decreased FA in many white matter regions and most of the changes appeared to be bilateral. The most significant differences were observed in the genu and body of the corpus callosum, superior longitudinal fasciculus (SLF), anterior cingulate fasciculus, thalamus, anterior commissure, internal and external capsules, and left superior temporal gyrus white matter. The TBSS results were similar yet they also revealed some significant differences in the right superior temporal gyrus as well. **Mean Diffusivity:** Group differences in MD were much more significant and extensive in the conventional voxel-based analyses as compared with the TBSS results. The MD appeared increased in the autism group and most differences appeared bilaterally. The most significant group differences were observed in the corpus callosum, the centrum semiovale including the superior longitudinal fasciculus, internal and external capsules, temporal stem, superior temporal gyrus, anterior commissure, thalamus, and anterior cingulate cover. In particular, the MD differences appear more substantial in the VBA. **EV3:** The third (smallest) eigenvalue demonstrated the most consistent and largest group difference (increased in autism) using VBA. Most of the regions with significantly increased MD also showed significantly increased EV3. Ironically, the TBSS method appeared to be less sensitive to group differences in the EV3 maps. **EV1:** The largest eigenvalue demonstrated far less significant group differences than any of the other DTI measures. Interestingly, many of the significant EV1 differences were in regions with crossing WM tracts. More significant differences were observed in using the TBSS analysis in the bilateral temporal stem and SLF.

## Discussion

In this study, a group comparison of DTI measures in autism versus controls for older children and young adults was performed using advanced voxel-based analysis methods – T-SPOON and TBSS. Diffuse group differences across much of the cerebral WM were detected for FA, MD and the EV3 measure. Far fewer differences were detected for the EV1 measure. In a comparison between T-SPOON and TBSS, the T-SPOON approach appeared to be much more sensitive to group differences. Both methods used the same image co-registration so this result was somewhat surprising. Further investigations are being performed to evaluate the differences in performance of T-SPOON and TBSS. One advantage of T-SPOON is that regional differences can be detected more easily. One disadvantage is that the smoothing can blur the signals between neighboring WM regions. The specific biological mechanism of the group DTI differences in autism are still unclear. The increased EV3 may reflect differences in either myelination or axonal density. Regardless, the differences appear to be consistent with the hypotheses of abnormal brain connectivity in autism.

## References

[1] Courchesne E, Pierce K. *Curr Opin Neurobiol* 15:225 (2005). [2] Barnea-Goraly N et al. *Biol Psychiatry* 55:323 (2004). [3] Alexander A et al. *NeuroImage* 34:51 (2007). [4] Keller T et al. *Neuroreport* 18: 23 (2007). [5] Lee J et al. *Neurosci Letters* 424: 127 (2007). [6] Lee J et al. *NeuroImage* (in press). [7] Smith S et al. *NeuroImage* 31:1487 (2006). [8] Woods et al. *Journal of Computer Sci Tomography* 22:139 (1998). [9] Smith and Nichols. *NeuroImage* 44:83 (2009).



**Figure.** Voxel-based group difference analyses comparing autism and controls in FA, MD, EV3 and EV1. Comparison of T-SPOON and TBSS results for same coronal slice. In general, the T-SPOON and TBSS results are similar although the T-SPOON approach appears to be more sensitive to group differences. The results are thresholded at a corrected p<0.01. The EV3 measure shows diffuse differences across much of the cerebral WM.