

Dynamic Imaging of Dual Contrast-Enhancement Using a Combined MR-Optical Imaging System

M. B. Unlu¹, Y. Lin¹, O. Nalcioglu¹, and G. Gulsen¹

¹JOHN TU & THOMAS YUEN CENTER FOR FUNCTIONAL ONCO-IMAGING, UNIVERSITY OF CALIFORNIA, Irvine, CA, United States

Purpose: It has been shown that dynamic contrast enhanced (DCE) MRI detects malignant cancers which are occult on mammography and ultrasound, and as such it is becoming the most popular imaging modality for screening young women with a high risk of developing breast cancer. However, despite its high sensitivity, DCE-MRI also detects many benign lesions. The available MR contrast agents used in clinical DCE-MRI are low molecular weight extracellular agents, which can diffuse freely from the vascular space into the interstitial space. Hence, some benign lesions that have relatively high vascularity and high interstitial volume may also show malignant type enhancement kinetics and give false positive results. There have been a number of studies using macromolecular MR agents to probe the vascular volume and permeability in a more sensitive manner. The most popular agent is albumin-Gd-DTPA, approximately 90 kD, which is mainly used to characterize vascular properties. Unfortunately, due to its large size (thus slow tumor uptake and relatively low tumor contrast) and potential protein toxicity, it has no potential for clinical applications. However, mid-sized macromolecular agents, which are large enough to be blood pool agents but small enough to be effectively excreted by the kidneys, may have a clinical potential.

An alternative solution is to use a second imaging modality additional to MRI along with a mid-sized contrast agent that this additional modality is sensitive to. We are currently developing such a combined dynamic MR-Optical system for human and animal imaging. The optical imaging system is a frequency domain diffuse optical tomography (DOT) system that has a great clinical potential in breast imaging, especially in providing complementary information to improve breast cancer diagnostic specificity. As an extra benefit of the combined system, optical imaging may provide not only total hemoglobin, oxygen saturation and scattering information based on the endogenous contrast, but also enhancement kinetics of an exogenous mid-sized probe [1, 2].

Methods: An R3230 ac induced small animal breast tumor model was used in this study. Tumor cells were injected into a Fisher rat that weighed 170 grams. The tumor size was approximately 2 cm. We used a frequency domain DOT system integrated into a 4T MR scanner. The time resolution of the imaging system was a pivotal feature of the dynamic studies. Our frequency domain DOT system has 8-source and 8-detector sites with a time resolution of 16 seconds per time point. The time resolution of dynamic MR data acquisition was set to 23 seconds. Optical measurements were performed with a laser diode emitting at 785 nm and modulated at a frequency of 100 MHz. The MR and the DOT measurements were started and performed simultaneously. A mixture of Gd-DTPA (0.1 mmol/kg) and ICG (0.5 mg/kg) was injected intravenously to the animal after the first three T1 weighted baseline acquisitions. Data was acquired by both systems for approximately 10 minutes.

Afterwards, the calibrated optical data was analyzed using the diffusion equation with the Robin boundary conditions. We used the finite element method for the numerical solution of the diffusion equation. In the optical reconstructions, the first time point was selected as the baseline, and then, it was subtracted from subsequent dynamic optical data. Co-registration of MR and optical images was accomplished using agar-water based markers attached to the DOT fiber probes. These markers were visible on the MR images so that contact points of the fibers on the animal surface could be located. It was important to take into account of the heterogeneity of the tumor when calculating the contrast agent kinetics. The availability of both the T1 and T2-weighted images made it possible to select a viable and a nonviable region in the tumor. A viable region characterized by (1) high signal (bright regions) on the MR enhancement image, and (2) normal or low signal (dark regions) in the T2 image. Accordingly, a nonviable region of the tumor was defined as a region that did not show T1 signal enhancement. We divided the entire tumor into two regions: one viable and one nonviable region. These ROIs were selected from MR enhancement images corresponding to the optical imaging slice. After the DOT reconstruction was completed, the mean of reconstructed absorption (μ_a) in each ROI at each time point was used to obtain the fractional absorption enhancement ($\delta\mu$) curve that was defined as $(\mu_a(t) - \mu_a(t=0)) / \mu_a(t=0)$. Similarly, fractional MR signal enhancement was defined $(S_{T1(t)} - S_{T1(t=0)}) / S_{T1(t=0)}$.

Results: Figure 1a shows the fractional enhancement for T1-weighted signal obtained by MRI from the nonviable and the viable ROIs. It was clear that the nonviable region exhibited low enhancement, and there was a higher signal enhancement in the viable region. In the viable ROI, Gd-DTPA kinetics showed a rapid rise. This was due to the fact that small molecular contrast agent leaked out of the blood vessels in the viable region causing a rapid increase in the signal that reached the peak point immediately after the injection. The slow decay seen afterwards showed that the Gd-DTPA started diffusing back into the intravascular space. Optical absorption enhancement kinetics is displayed in Figure 1b. Absorption kinetics showed a rapid rise in the viable region similar to MRI and a slow decay was observed. The reason is that the large molecular size of albumin-ICG made it difficult for the contrast agent to exchange between the extravascular and intravascular spaces. Meanwhile, the kinetics in the nonviable ROI showed low enhancement.

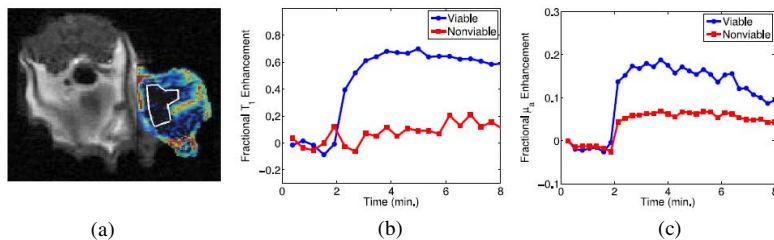


Figure 1. (a) T1-weighted MR image at the peak signal enhancement. ROI covers the nonviable region of the tumor. (b) Fractional T1 enhancement. (c) Fractional optical absorption enhancement in the viable and nonviable regions.

Discussion: DOT imaging allowed spatially resolved measurement of absorption kinetics within the tumor. 16-second temporal resolution of our system allowed to measure the fast-rising slope of absorption enhancement and recover the peak value of the optical absorption. It had been shown that reduced scattering did not depend on the concentration of ICG significantly. Therefore, we calculated only the absorption kinetics. The spatial resolution of DOT was low compared with the MRI. As a result, recovered optical enhancement map did not entirely overlapped with the MR enhancement map. This suggested that structural *a priori* information obtained from MRI should be used in optical reconstruction.

Some qualitative features of both contrast agents could be observed from the kinetic curves in the viable ROI. The kinetics of Gd-DTPA displayed the characteristics of a small molecular weight agent whereas ICG kinetics showed the features of a large molecular agent. In addition, neither agent showed a significant enhancement in the nonviable region. These results were consistent with the DCE-MRI literature.

Using two contrast agents, one small molecular weight MR and one large molecular weight optical agent, during a single imaging session provides fully co-registered complementary information. This study was the first step towards the goal to use optical imaging in conjunction with the DCE-MRI to improve specificity in tumor characterization.

References: [1] Intes X, et al, Med Phys. 30: 1039-47 (2003). [2] Cuccia DJ, et al, Appl Opt.42: 2940-50 (2003) [3] Su MY, et al., J. Mag. Res. Img.9: 177-86, (1999).

Acknowledgment: This research was supported in part by the National Cancer Institute through Grants \# R21/33 CA-101139, \# R21/33 CA120175, \# R21 CA 121568, \# U54 CA105480, the California Breast Cancer Research Program No. 12IB-0095, and U.S. Army BC051304.