

Flow Saturation Inversion Recovery Non-Contrast-Agent MR Angiography for lower extremity

M. Miyoshi¹, N. Takei¹, and T. Tsukamoto¹

¹Japan Applied Science Laboratory, GE Yokogawa Medical Systems Ltd., Hino, Tokyo, Japan

Purpose

The importance of the Non-Contrast Agent MR Angiography (NCA-MRA) is increasing in the extremity region to avoid using contrast agent. NCA-MRA often uses image subtraction for arterial/venous separation. However, image subtraction is sensitive to patient motion. In this paper, Inversion Recovery (IR) pulse is used to eliminate subtraction and the image quality is compared between subtraction method and IR method.

Introduction

Fresh Blood Imaging (FBI) is one of NCA-MRA [1]. Because of flow void, FSE signal intensity changes between systolic and diastolic phase. Subtraction between these phase images results in flow image. Data acquisition is restricted to FSE and the flow void is controlled with the area of FID crusher gradient pulses.

Flow-Saturation-Preparation (FSP) saturates fast flow (arterial) signal with preparation pulse [2]. FSP is applied in systolic phase and the subtraction between FSP and control images (FSP-subtraction) results in flow image. The flow signal intensity is quantitatively controlled with Velocity ENCoding (VENC) gradient pulses. Data acquisition is not restricted and FSE [2] or SSFP [3] were used.

We introduce Flow Saturation IR (FS-IR) in this paper. FSP saturates fast flow (arterial) and preserves slow (venous) flow or stationary fluid. Then, Adiabatic IR pulse inverts all magnetization non-selectively. After waiting the T1 relaxation for inversion time (T1), image data is acquired at the null point of venous signal. The arterial signal is recovered and separated from vein. Because this method does not use subtraction, it is less sensitive to patient motion and scanning time is shorter than the other methods.

Methods

Pulse sequence chart is in Fig. 1. FSP was applied in systolic phase. Data acquisition was FSE, which is less sensitive to B0 inhomogeneity. Data acquisition timing was set in diastolic phase to avoid flow void. T1 was the time between IR and FSE and it was optimized based on T1 of vein. STIR was used for homogeneous Fat suppression. Time between FSP and IR was automatically modified based on above conditions and cardiac rate.

Signal intensity was simulated to optimize T1. T1 was assumed to be 1200 ms for artery and vein, 250 ms for fat.

Popliteal arteries and trifurcation were scanned for three volunteers in 1.5T scanner (HDx GE Healthcare). T1 was optimized between 1100 to 1500 ms. Signal intensity of popliteal arteries, scanning time and image quality were compared between FSP-subtraction and FS-IR. Protocols were as follows; TR=3-5RR, TE=75-100ms, FOV 40-45cm, Thick 3mm, #slice 30, matrix 256*256, Flow Compensation, Peripheral gating, scanning time 2-3 minutes. VENC was set to the slower value than the flow velocity of each volunteer's popliteal arteries, which were measured prior to the scan with 2D Gated Phase Contrast.

Results

In the simulation, optimal T1 was between 1200-1300 ms (Fig. 2).

In the volunteer scans, optimal T1 was also between 1200 (Fig. 3). The venous signal was increased in longer T1 cases and the arterial signal was too weak in shorter T1 cases. Signal intensity of popliteal arteries of FS-IR was 66% of the FSP-subtraction, in average. Scanning time of FS-IR was 89% of FSP-subtraction, in average. Large arteries were depicted in both methods. Small arteries were depicted better in FSP-subtraction. Venous signal was higher in FS-IR.

Discussion and Conclusion

Because additional IR was used for FS-IR, signal intensity was lower than FSP-subtraction. However, Patient motion is a tough problem for subtraction method. FS-IR didn't require subtraction and arteries depiction was comparable in shorter scanning time. Because FS-IR can eliminate subtraction, it is an effective method for NCA-MRA.

Reference

- [1] Miyazaki M. et al., Radiology 227:890-896, 2003.
- [2] Miyoshi M. et al., ISMRM 2007, 180.
- [3] Miyoshi M. et al., ISMRM 2007, 2495.

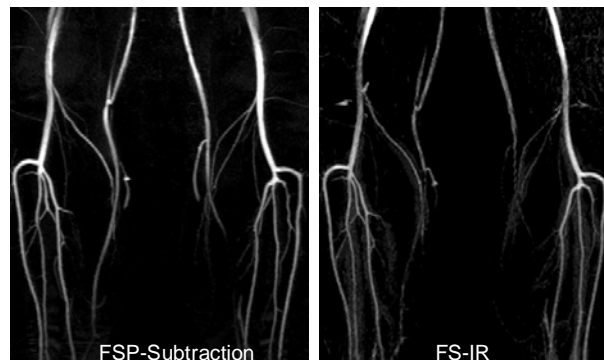
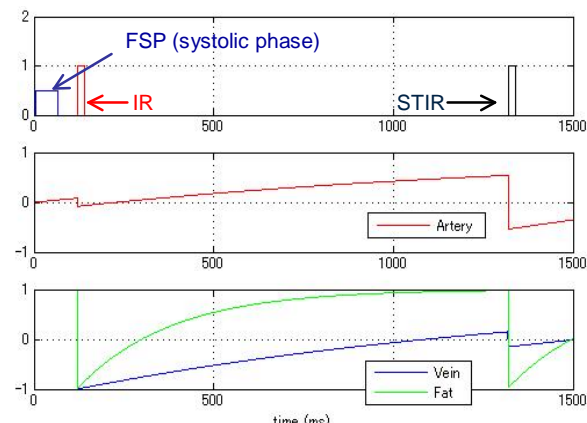
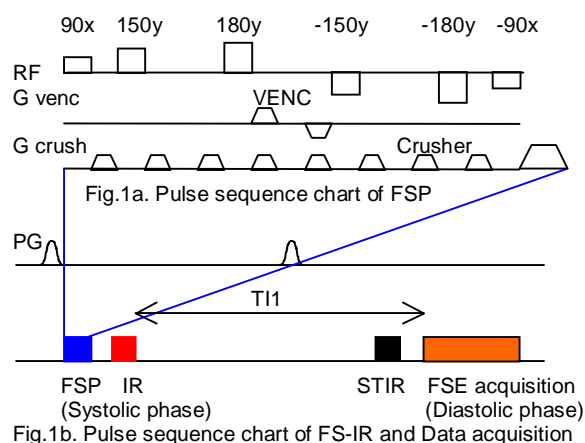


Fig. 3 : Volunteer result. Left: FSP-subtraction, Right: FS-IR