

Feasibility of combined low-dose (0.07mmol/kg) continuous table movement MRA of the peripheral vessels with ultra-low dose (0.03mmol/kg) TWIST-MRA of the calf station

H. J. Michaely¹, M. Voth¹, S. Haneder¹, and S. O. Schoenberg¹

¹Institute of Clinical Radiology and Nuclear Medicine, University Medical Center Mannheim, Mannheim, Germany

Introduction

MRA is the clinical standard for vascular imaging of the lower extremities. In critically ill patients with PAOD III or higher or ulcers the calf station is often impaired by venous overlay. Therefore, time-resolved MRA acquisitions of the calves are often applied additionally. However, many patients scheduled for peripheral MRA also suffer from chronic renal failure. In these patients the minimization of administered contrast agent dose seems appropriate to minimize the risk of NSF [1]. Therefore, the purpose of this study was to proof the concept of peripheral continuous table movement (CTM)-MRA [2] in combination with high spatial and temporal resolution (TWIST)-MRA of the calf station in a single MR-exam at 3.0T in total with a single dose (0.1 mmol/kg) of gadobutrol.

Materials and Methods

After IRB approval, 19 consecutive patients (13m/6f, mean age 63.5 years) referred for peripheral MRA with clinical symptoms of peripheral arterial occlusive disease Fontaine stages II–IV were included. All of them underwent both CTM-MRA (TR 2.4ms/ TE 1.0ms/ flip angle 21°, continuous z-axis FOV 1280mm, GRAPPA 2, 1.2mm isotropic spatial resolution) of the entire run-off vessels and TWIST-MRA (TR 2.8ms/ TE 1.1ms/ flip angle 20°; sampling density central k-space 15%, peripheral k-space 20%, 1.1mm isotropic spatial resolution, 5.5s temporal resolution) of the calf station during a single MR-exam. All examinations were performed on a 3.0T MR system (Siemens Tim Trio). A total of 0.1 mmol/kg BW gadobutrol (Gadovist 1.0M, Bayer Schering Pharma) a macrocyclic gadolinium-based contrast agent was injected at a flow rate of 1.5 mL/s of which 0.07mmol/kg was administered for the CTM-MRA and 0.03mmol/kg for the TWIST-MRA. Each injection was followed by a 30ml NaCl chaser at the same flow rate.

19 vessel segments of each CTM-MRA run off datasets were qualitatively assessed by one experienced radiologist using a four point scale (4-excellent, 1-non-diagnostic) followed by the assessment of 6 vessel segments of each TWIST-MRA. Additional relevant findings only visible in the TWIST-MRA were documented.

Results

All datasets could be evaluated (Figure 1), no adverse events occurred. In two patients with amputations not all segments could be assessed. In total, 349 vessel segments was assessed with CTM-MRA. CTM-MRA was diagnostic in 99% (346/349 segments) with excellent or good image quality in 95% (332/349 segments). Moderate image quality was found in 4% (14/349). Due to bolus timing errors 3 segments (1 %) were not assessable. The median image quality was worst in the internal and external iliac artery (median 3-3.5) while all other vessel segments were rated with a median of 4. TWIST-MRA was diagnostic in 100% (107/107 segments) all with excellent or good image quality. In 10 of 19 patients additional relevant findings were detected by TWIST-MRA including small collaterals not seen on CTM-MRA and altered hemodynamics (Figure 2).

Conclusion

Single-dose gadobutrol MRA with CTM in combination with a high spatial and temporal resolution sequence TWIST at 3.0 T is a reliable technique with good image quality. Despite the use of single dose contrast agent only, large field of view coverage and dynamic images can be acquired. This imaging approach of the vasculature has great potential for a broad clinical use particularly in patients with impaired renal function.

Figure 1

Full thickness MIP image of the CTM-MRA demonstrating bilateral tibial artery stenoses. The vessels of the pelvis and thighs are not narrowed. For this CTM-MRA 5ml gadobutrol were administered.

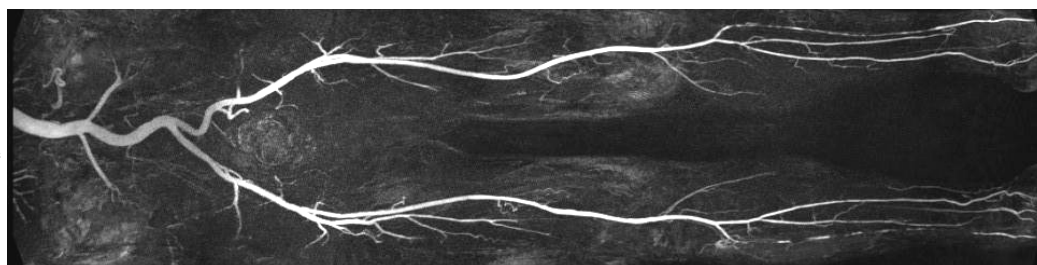
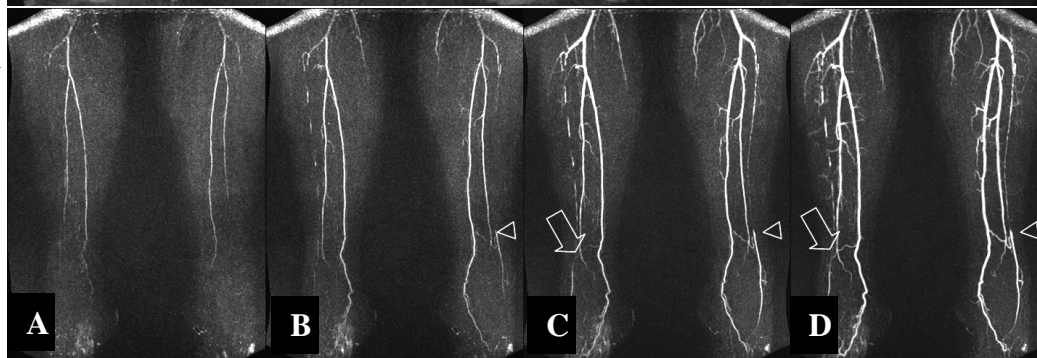


Figure 2

4 MIP views of the time-resolved MRA of the same patient acquired after administration of 1.5ml gadobutrol demonstrating collateral vessels supplying the left (arrowhead) and the right (arrows) anterior tibial arteries which reveal multiple proximal stenoses bilaterally. (A-D represent four frames, each 5.5s apart)



References

1. Broome DR, et al. AJR Am J Roentgenol. 2007
2. Kramer H, et al. Invest Radiol. 2008