

Proton MRS investigation of human glioma models in nude mice at 14.1 T

V. Mlynarik¹, C. Cudalbu¹, V. Clément², D. Marino², I. Radovanovic², and R. Gruetter^{1,3}

¹Laboratory of Functional and Metabolic Imaging, Ecole Polytechnique Fédérale de Lausanne, Lausanne, Switzerland, ²Dept. of Genetic Medicine and Development, University of Geneva School of Medicine, Geneva, Switzerland, ³Departments of Radiology, Universities of Lausanne and Geneva

Introduction: Injecting human glioma-initiating cells into brain of immunodeficient rodents is a recently introduced model for studying properties of human gliomas. Fresh human glioma cells implanted into immunodeficient rats produced slowly growing, invasive tumors with little neovascularization, whereas serial passaging of these cells in animals led to rapidly growing, less differentiated and vascularized tumors (1). Proton spectra of gliomas at lower magnetic fields show only few resolved spectral lines, thus limiting the number of metabolites to be quantified. In this study, separated human glioma-initiating fresh cells (FC) and cultured cells (CC) (2) were injected into the brain of nude mice. The aim was to study the effect of tumor development on the metabolism of brain tissue in the injected site and to measure the metabolic profiles of the gliomas formed from FC and CC at 14.1 T.

Methods: Human glioma-initiating cells were injected into the striatum of ten nude mice. Five mice having injected FC were examined 3-4.5 months after the injection, another five animals injected with CC were measured before and on days 7, 14, 21, 28, 35 and 42 after the cell injection on a 14.1 T/26 cm Varian animal scanner. A two-loop quadrature coil with dimensions of 21 mm × 14 mm was used as a transceiver. The protocol consists of T2-weighted axial imaging followed by short echo-time (TR/TE = 4000/2.8 ms) SPECIAL (3) proton MR spectroscopy from a VOI ~ 10 µL located inside a tumor or, before detecting solid tumor, at the injection site and symmetrically in the contralateral hemisphere. Finally, a series of T1-weighted images were measured after intraperitoneal administration of Gd(DTPA).

Results: Tumors grown from CC appeared in the injection sites on both T2- and post-contrast T1-weighted MR images on days 28 or 35 and showed necrosis and Gd enhancement. The gliomas from FC appeared after about 3 months and showed no necrosis and very little Gd enhancement. Interestingly, before detecting solid tumors from CC (days 7 to 21) the spectra from the hemisphere injected with CC showed a gradual, about 15 % decrease in concentration of NAA+NAAG and glutamate (Glu), a 40 % decrease in glucose (Glc), a 30 % increase in glycine (Gly) but no change in choline (PCho+GPC) (Fig. 1). Well resolved spectra of solid tumors were obtained (Fig. 2) and metabolite concentrations of 17 metabolites were determined. The spectra of solid tumors grown from CC (Fig. 2c) showed dramatic changes of many metabolites compared to the contralateral hemisphere including intense peaks of lipids, a 3- to 5-fold decrease in NAA+NAAG, Cr+Pcr, Gln+Glu, GABA, and taurine (Tau) and a 2- to 5-fold increase in PCho+GPC, Gly, alanine (Ala) and lactate (Lac). The metabolic profile of the tumors grown from FC (Fig. 2b) was slightly different, with myo-inositol (Ins) about 100 % higher and PCho+GPC about 50 % higher than in the tumors grown from CC. In addition, the concentrations of Cr+Pcr, Lac and Ala in the tumors from FC were almost the same as in the normal tissue and no lipid peaks were detected.

Discussion and Conclusions: Our experiments demonstrate that changes in concentrations of a number of metabolites can be detected in brain tissue prior to overt tumor formation. The changes in metabolite concentrations at the injection site of CC are in an excellent agreement with metabolic changes observed in tumor surroundings in patients (4). Thus, nude-mice model seems to be suitable for studying tumor infiltration, which is important in therapy management and surgical planning. The different metabolic profiles of tumors formed from FC and CC agree well with spectral features of lower- and higher-grade gliomas, respectively, observed in humans (5). In conclusion, high-field MR spectroscopy is capable of detecting early stages of a malignant process in brain and could be useful in distinguishing between various grades of gliomas.

Acknowledgments

This study was supported by Centre d'Imagerie BioMédicale (CIBM) of the UNIL, UNIGE, HUG, CHUV, EPFL and the Leenaards, Jeantet and Anita et Werner Damm-Etienne Foundations.

References

1. Thorsen F *et al.* NMR Biomed. 21:830, 2008. 2. Clément V *et al.* Curr Biol. 17:165, 2007. 3. Mlynarik V *et al.* Magn Reson Med. 56:965, 2006. 4. Stadlbauer A *et al.* Invest Radiol. 42:218, 2007. 5. Guillemin R *et al.* J Neurooncol. 87:181, 2008.

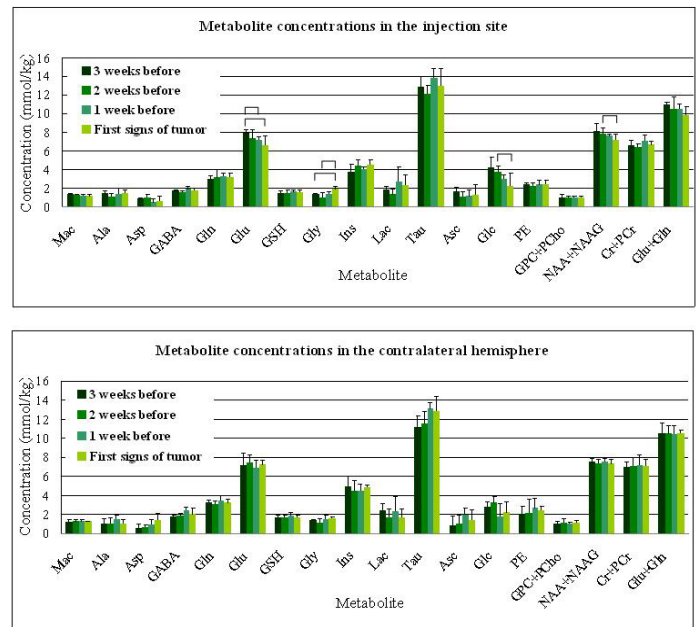


Fig. 1. Absolute concentrations of metabolites in the injected and contralateral hemispheres at various time points before appearing solid tumors. The marked concentrations were significantly different.

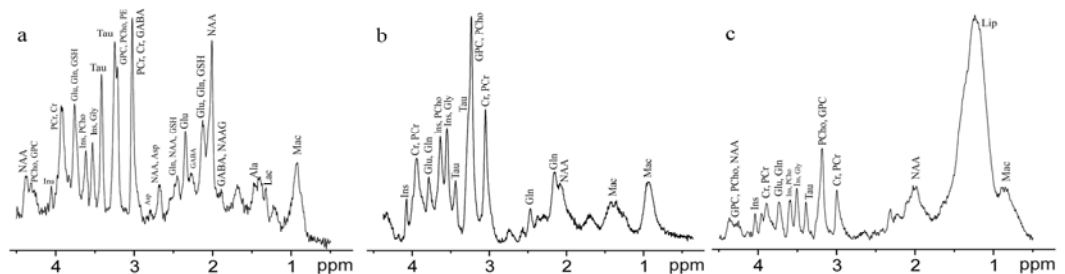


Fig. 2. Proton spectra of mouse brain from the contralateral side (a), from tumors grown from FC (b) and from CC (c)