

Correlation between Apparent Diffusion Coefficient values and Pfirrmann grades of Lumbar Intervertebral Disc Degeneration

H. J. Yu¹, S. Bahri¹, L. T. Muftuler¹, O. Nalcioglu¹, and V. Gardner²

¹Tu & Yuen Center for Functional Onco-Imaging, University of California, Irvine, CA, United States, ²Orthopaedic Education and Research Institute of Southern California, Orange, CA, United States

Purpose:

The role of MRI in study of IVD (intervertebral disc) degeneration is increasingly becoming more important. Nowadays, lumbar disc degeneration is typically classified based on routine T2w-MRI, utilizing a well-accepted grading system such as Pfirrmann's [1]. A morphologic grading system such as Pfirrmann's allows a standardized assessment of IVD degeneration and has been found to be reliable [2]. However, such grading system is ultimately based on subjective criteria and its value for *in-vivo* study of IVD degeneration in a more quantitative setting has not been fully investigated. In this study we analyzed ADC (apparent diffusion coefficient) values from lumbar IVD on pixel-by-pixel basis to investigate the correlation between ADC and Pfirrmann grades. The pixel-by-pixel ADC values were obtained from the whole IVD and then grouped within each grade for analyses and comparison.

Methods:

One-hundred-sixty-six lumbar IVDs from 34 subjects (mean: 39 yrs; range: 19–64 yrs) were included in this study. Each subject was scanned on a 3T Philips scanner (Philips Medical Systems, Best, Netherlands) for sagittal T2w and DWI. The DWI protocol was based on a single-shot EPI (FOV/thickness=330/3mm, TR/TE=2672/62ms, acquisition-matrix=164x160 (176x176 image-matrix)), and performed with two b factors (b=0 and 600 sec/mm²) in each of the three orthogonal directions for generation of a rotationally invariant ADC-map in identical geometry as that of the T2w. The level of degeneration was classified according to Pfirrmann's 5-level grades [1], normal (1) to severe degeneration (5), on the mid-sagittal T2w image. The ROI for the whole IVD was drawn on either the T2w or DWI (b=0) images, and the resulting pixel-by-pixel ADC values were collected for each IVD and grouped for each grade. The pixel-distribution of ADC was compared using a normalized histogram approach in order to account for different numbers of pixels belonging to different grades. The maximum cut-off value of ADC used in the histogram analysis was 2.5x10⁻³ mm²/sec, which is the ADC value of pure water at 40°C [3], and the bin-width was set at 0.5x10⁻³ mm²/sec resulting in a 5-bin histogram.

Results:

Fig.1 shows examples of T2w image and the corresponding ADC-map. Table 1 summarizes the distribution of included IVDs in different degeneration levels and the mean population values of ADC. Fig.2 plots the mean ADC values (±SD), which indicates a clear downward trend for the mean ADC value as the degeneration of IVD becomes more severe. Unbalanced ANOVA test showed that each group mean is statistically different from the other 4 (p<0.05). Fig.3 shows the histogram bar-graphs of the normalized percentile-frequencies from the group data of 5 Pfirrmann grades side-by-side. It shows the population break-down in different ranges of ADC value for the observed downward trend in the mean ADC value. Although the number of IVDs in grade 1 and 5 is relatively small compared to those in the middle 3 grades, it is clear that the majority of pixel population (>50%) show high ADC values (1.5–2.5x10⁻³ mm²/sec) for more 'normal' IVD (grades 1 & 2); for more 'degenerated' IVD (grades 4 & 5) the majority show low ADC values (0–1.0x10⁻³ mm²/sec). Small percentages of pixels (<1.5% for grades 2-5 and 6.6% for grade 1) showed ADC values higher than 2.5x10⁻³ mm²/sec, which were attributed to contribution from CSF and/or small capillary-level perfusion and excluded from the analyses.

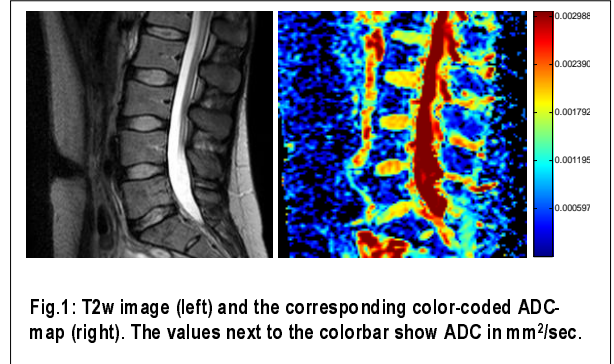


Fig.1: T2w image (left) and the corresponding color-coded ADC-map (right). The values next to the colorbar show ADC in mm²/sec.

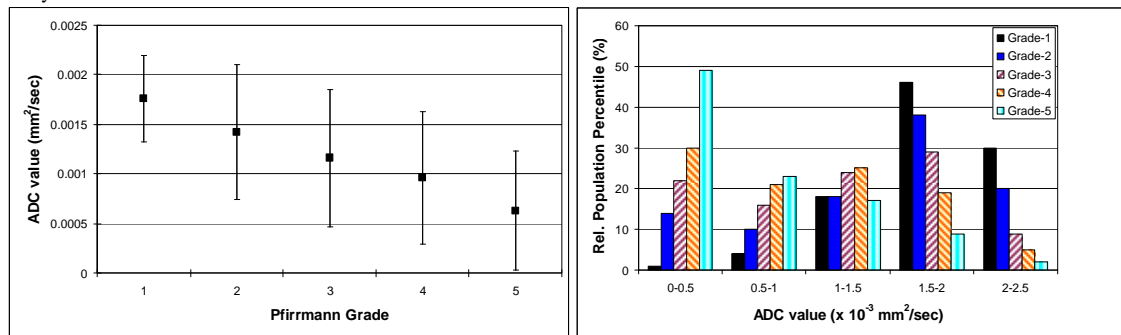


Fig. 2 (left): The plots of the mean values of ADC (±SD) for each Pfirrmann grade group. Fig. 3 (right): The normalized population frequencies from the 5 different grades are plotted side-by-side based on the 5-bin histogram analysis. Those values on the horizontal axis represent the ranges of ADC value used for the 5-bin histogram analysis.

Pfirrmann grade	IVD #	ADC (mean±SD)
1	2	1.76±0.43
2	89	1.42±0.68
3	37	1.16±0.69
4	31	0.96±0.67
5	7	0.63±0.60

Table 1: Degeneration levels based on Pfirrmann grades (1 – 5) and the distribution of included IVDs. The values under 'ADC' are in 10³ mm²/sec.

Discussion:

The results show a clear correlation between the Pfirrmann classification and ADC values of lumbar IVD, which reflects the multifactor changes taking place in IVD degeneration process, in this case the gross morphological changes as measured by Pfirrmann classification and ADC. This is consistent with the findings by others who have also utilized ADC measurement, all which were, however, based on their own degenerative classification and ROI-averaged measurement of ADC. Our findings based on pixel-by-pixel analysis of ADC are very indicative of the anatomic consideration of IVD, consisting of the nucleus pulposus (NP) and the peripheral annulus fibrosus (AF). The large shifts in the ADC related to degeneration are disproportionately due to the part of disc with relatively high ADC value (>1.5) to begin with in normal disc (NP), and some part of disc does not seem to reflect much degenerative related changes in ADC (1–1.5), which could be attributed to AF.

References: [1] Pfirrmann et al. Spine 2001; 26(17):1873-8. [2] Wilke et al. Eur Spine J 2006; 15: 720-30. [3] Le Bihan et al. Radiology 1988; 168:497-505.

Acknowledgement: Funding support from CardioVascular BioTherapeutics (CVBT), Inc.