

## Contrast enhanced MRA with retrospective selection of acceleration factor

B. Wu<sup>1</sup>, R. Watts<sup>2</sup>, A. Butler<sup>1</sup>, R. Millane<sup>1</sup>, and P. Bones<sup>1</sup>

<sup>1</sup>Department of Electrical and Computer Engineering, University of Canterbury, Christchurch, New Zealand, <sup>2</sup>Department of Physics and Astronomy, University of Canterbury, Christchurch, New Zealand

**Introduction** A new 3D time resolved contrast enhanced MR angiography (CE-MRA) technique is presented that uses both parallel MRI (pMRI) and an object support constraint to enable high temporal and spatial resolution imaging. The k-space data acquisition is such that the acceleration factor can be chosen in post-processing, enabling a temporal window to be chosen to give an optimum, high SNR arterial view. This technique allows both temporal dynamic to be assessed while not compromising SNR for a single peak arterial phase image. An object support constraint is incorporated to improve the reconstruction SNR.

**Theory** The proposed k-space data acquisition scheme is illustrated in Fig. 1: with a given block size, the plane defined by two phase encoding (PE) directions is decomposed into subsets each of which corresponds to frequency encoding (FE) lines at a particular position in *all* the repeated blocks (Fig. 1a, each dot represents an FE line). These subsets are acquired in a pre-defined order (Fig. 1b). Any groups of sequentially acquired subsets therefore form a periodic sampling pattern at reconstruction. The utility of a periodic sampling pattern is to decompose the overall pMRI encoding matrix, and hence achieve a computationally efficient matrix inversion [1]. In post-processing, sliding window (SW) reconstructions using these sequentially acquired subsets can be made with arbitrary window length and position on the temporal axis.

Since the sampling pattern used at reconstruction has a large influence on the conditioning of matrix inversions [2], the sequential acquisition order of the k-space subsets is of particular importance. We determine the order using a sequential forward selection (SFS) based on minimizing the reconstruction noise power [3].

Knowledge of the object support allows free air region to be excluded from reconstructions and hence improves the conditioning of the matrix inversion [2, 4]. Subtraction of a non-contrast data set allows the anatomical background to be suppressed so that the resulting data is only contributed by regions containing contrast and hence features a much reduced support region. A loose support constraint of the vascular region can be straightforwardly obtained from the full data set in post-processing.

**Method** A coronal 3D scan (fast spoiled gradient echo) of the calf of a healthy volunteer was obtained using a 1.5T GE scanner. 20ml of Gd-BOPTA (Multihance®) was injected as a bolus. A matrix size of 256×128×48 was used to obtain a spatial resolution of 0.9×0.9×1mm. TR/TE = 5.4/1.6 ms, flip angle = 45°. Complete acquisition of the 3D k-space volume took 35s, and 5 repetitions were made. Data acquisition started 20s before contrast injection so that no contrast was presented for the first k-space repetition; that data was used for estimating the coil sensitivity profile and subtracted from following repetitions to suppress the anatomical background.

**Results and discussion** SW reconstructions based on the subtracted data sets (k-space repetitions 2 to 5) were first made at a high temporal resolution, from which the temporal intensity plots of an arterial voxel and a venous voxel were generated (Fig. 2a). Note that the periodic variations are due to the non-uniform k-space energy distribution among the subsets. The temporal window that gave an arterial contrast phase with good temporal resolution was identified (SW1), based on which a coronal MIP was obtained (Fig. 2b). In comparison, a coronal MIP reconstruction containing both arterial and venous phase (SW2) is shown in Fig. 2c; the latter demonstrates a better SNR at the cost of temporal resolution.

In Figs. 2d and 2e, reconstructions of an axial slice using the original and subtracted data set are compared, and in the latter case a loose support constraint was incorporated. A much better SNR of the vascular region (arrowed) was obtained in the latter case.

**Conclusion** We have proposed a new 3D CE-MRA method which allows the temporal window length to be flexibly chosen in post-processing. It hence achieves an improved trade-off between temporal resolution and SNR.

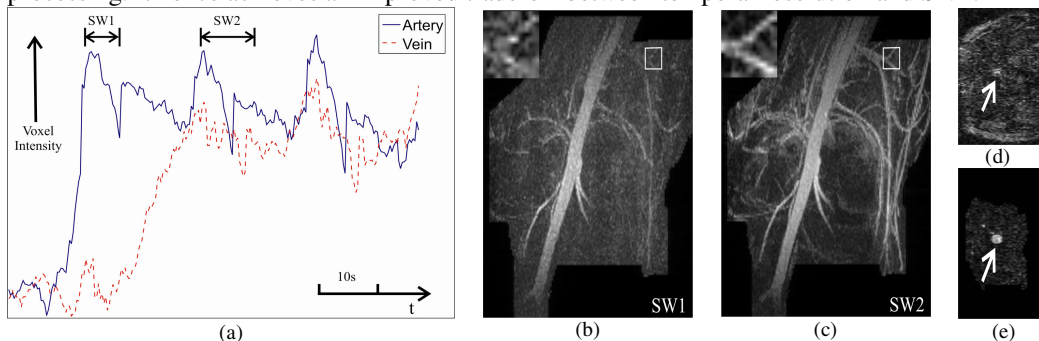


Figure 2: SW reconstructions: (a) temporal contrast intensity plots of an arterial voxel and a venous voxel which allow the placement of SW1 and SW2 on the temporal axis, leading to the MIP reconstructions shown in (b) and (c) respectively. Axial slices (d) and (e) demonstrate the improvement in SNR resulting from background suppression and the resulting smaller support.

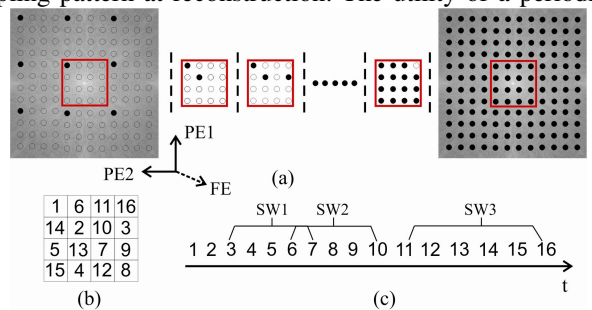


Figure 1: A repeating block size of 4×4 gives 16 k-space subsets, which are acquired sequentially (a, solid dots represent acquired FE lines.) in a designed order (b). SW reconstructions can be performed on arbitrary groups of k-space subsets as illustrated in (c).

## References

- [1] Blakeley ND, *et al.* JOSA A, 2003.
- [2] Wu B, *et al.* Proc. IVCNZ, 2007.
- [3] Reeves SJ, *et al.* IEEE Trans Signal Processing, 1999.
- [4] Pruessmann KP, *et al.* MRM, 1999.