

Localised cartilage assessment with three-dimensional dGEMRIC in subjects with normal and cam-type abnormal hip joint morphology. An assay of early disease.

T. C. Pollard¹, E. G. McNally¹, D. C. Wilson², B. Maedler³, D. R. Wilson², M. Watson¹, and A. J. Carr¹

¹Nuffield Department of Orthopaedic Surgery, University of Oxford, Oxford, United Kingdom, ²Department of Orthopaedics, University of British Columbia, Vancouver, BC, Canada, ³Philips Healthcare, Vancouver, BC, Canada

Introduction

It is increasingly accepted that the majority of cases of ‘idiopathic’ osteoarthritis (OA) of the hip are caused by subtle morphological abnormalities of the hip joint. Femoroacetabular impingement (FAI) describes a mechanism through which these abnormalities of the proximal femur and acetabulum cause localized damage to the articular cartilage. The majority of patients presenting with FAI have a ‘cam’ deformity, with an osseous bump or lack of offset at the anterolateral aspect of the head-neck junction (Figure 1). The geography of chondral damage resulting from cam-type FAI is well described, with initial delamination of the anterosuperior acetabular cartilage (on a clock-face representation of the acetabulum, this zone is from 12 to 3 O’Clock) with preservation of the femoral head cartilage. Although associations between cam lesions and cartilage degeneration have been shown at the time of surgery, there are no longitudinal data to confirm that cam lesions lead to OA, or that their surgical removal halts disease progression. There is an urgent need for a sensitive and responsive non-invasive assay of chondral damage so that the efficacy of early OA treatments can be evaluated. Delayed gadolinium enhanced MRI of cartilage (dGEMRIC) is a validated technique that permits inference of glycosaminoglycan (GAG) distribution in articular cartilage from measurements of the tissue T1 value after injection of the ionic MRI contrast agent gadolinium. Application of dGEMRIC to study clinical hip problems has focused on a single summary index describing the entire joint. Our objective was to determine whether there is a localized GAG loss in hips with cam deformities, who had not attended for medical treatment, using a three-dimensional (3D) dGEMRIC protocol.

Methods

Subjects were recruited from a prospective study examining the prevalence of OA of the hip in a group of 123 individuals with a family history of end-stage OA of the hip and their 80 spouse controls. All subjects underwent clinical assessment consisting of an interview and physical examination which included provocation tests for FAI. Standardised AP Pelvis and cross-table lateral radiographs of each hip were obtained in all subjects. Following review of the radiographs, subjects were selected for dGEMRIC scans. Only hips with a minimum joint space width of 2.5mm (i.e. normal) on the AP pelvic radiograph were considered for a scan. Cases were then further selected by the presence or absence of a cam deformity, as assessed by the alpha angle measured on the lateral radiograph. Hips with an alpha angle greater than 55 degrees were considered to have a cam deformity. 32 hips in 32 subjects were scanned: 21 with cam lesions (12 male, 9 female, mean age 50.8 years, 16 from the family history and 5 from the spouse control cohorts) and 11 non-cam (6 male, 5 female, mean age 53.5 years, 8 from the family history and 3 from the control cohorts). None of the cases selected had been investigated or treated for hip pain.

dGEMRIC protocol:

Following intravenous injection of gadolinium-(DTPA)²⁻, (0.2mM/Kg, Magnevist, Berlex Labs), a standardized exercise program consisting of a ten minute walk on a treadmill at 4kph, followed by 150 hip rotations was performed. Scans were performed using a 3T Philips Achieva scanner with two flexible surface coils around the hip. dGEMRIC imaging started 75 minutes post-injection in all cases. Our sequence protocol was: sagittal 3D FFE, TR_{eff}/TE/flip = 6.0ms/2.9ms/12°, inversion times TI = 2100, 1200, 600, 250, 105ms, FOV = 180 mm, matrix: 208 x 209 (interpolated to 512 x 512), 15 x 3 mm slices. Scan time was 45 minutes. To attain sufficient signal-to-noise at the short TIs, TR_{shot} was held constant at 2200ms for each T1.

dGEMRIC Analysis: All 3D scans were volume registered prior to analysis to compensate for any subject movement during the examination. Quantitative T1 maps were generated with custom programs (IGOR, Wavemetrics, USA) through pixel-based curve fitting of the magnitude signal intensities versus inversion times. The geometric center of the femoral head cartilage was identified. 2 regions of interest (ROIs) were manually segmented. The first was the acetabular cartilage from 12 to 3 O’Clock, on slices 6-8, matching the location of chondral damage in cam-type FAI (T1-Index_{acet}). The second ROI was the total cartilage (femoral and acetabular) for the whole joint from 9 to 3 O’Clock (T1-Index_{total}). The average of all pixels within the given ROI defined the T1-index for that region.

For each hip, the ratio of the GAG content in the anterosuperior acetabular cartilage as compared to the whole joint was determined by dividing T1-Index_{acet} by T1-Index_{total}. Comparison of the mean T1-Index_{total} and T1-Index_{acet} / T1-Index_{total} for the cam and non-cam groups was made using unpaired Student’s T-test.

Results

The Cam and non-Cam groups had similar T1-Index_{total} but the ratio T1-Index_{acet} / T1-Index_{total} was significantly lower in the cam hips, indicating relative depletion of GAG content in the anterosuperior acetabular cartilage in the cam hips but no generalised disease (Table 1). Cam hips with clinical signs of FAI had lower T1-Index_{total} than both cam hips with a normal examination (p=0.055) and non-cam hips (p=0.049) (Table 2).

Discussion

The principle employed in this study, whereby dGEMRIC is utilised to obtain ratios of GAG content for specific regions of interest relative to the joint as a whole, may reduce variability between subjects and help map chondral damage in different OA phenotypes in the hip and other joints. This may improve our understanding of early OA pathological mechanisms, and may be more helpful than a single measure of the overall joint cartilage GAG. The technique may be particularly useful for assessing the efficacy of surgical procedures which do not directly interfere with the region of interest, such as excision of cam lesions in FAI, and osteotomy around the knee. Subjects with cam lesions who have not yet sought medical treatment demonstrate relative depletion in the GAG content of their anterosuperior acetabular cartilage. This finding is in keeping with the pathomechanism of FAI described by Ganz. Furthermore, dGEMRIC was able to detect that those cases with positive clinical findings had evidence of more generalised joint disease. Although the recognition of widespread chondral abnormality in such individuals has important clinical implications, the largest subgroup in this study were those with cam lesions but no symptoms or signs. Understanding why these individuals are earlier in the disease process, and tracking their progression, will be key in order to select out the cases to treat, perhaps prophylactically, in the future.

Figure 1. Non-Cam and Cam hips with associated dGEMRIC colour maps

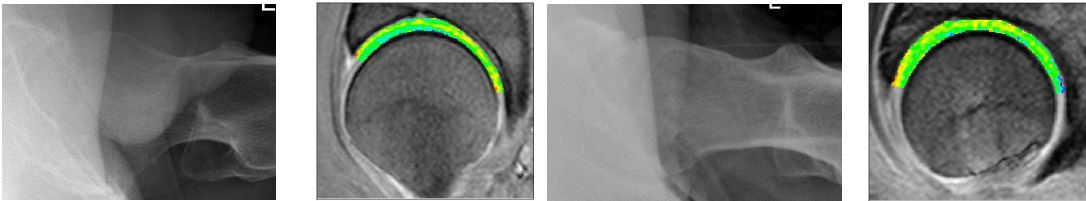


Table 1. dGEMRIC and alpha-angle findings for cam and non-cam hips

	Cam hips	SD	Non-Cam hips	SD	p value
T1-Index _{total}	689.4 ms	100.3ms	700.6 ms	83.7 ms	0.790
T1-Index _{acet} / T1-Index _{total}	0.933	0.079	1.013	0.085	0.017
Mean Alpha angle	70.6 deg	9.2 deg	47.8 deg	4.3 deg	<0.001

Table 2. dGEMRIC findings for cam and non-cam hips and clinical signs

	Cam hips				Non-Cam hips	
	Positive exam	SD	Negative exam	SD	Negative exam	SD
T1-Index _{total}	628.6 ms	77.6	717.4 ms	99.4	722.3 ms	66.8
T1-Index _{acet} / T1-Index _{total}	0.955	0.087	0.922	0.077	1.014	0.042