

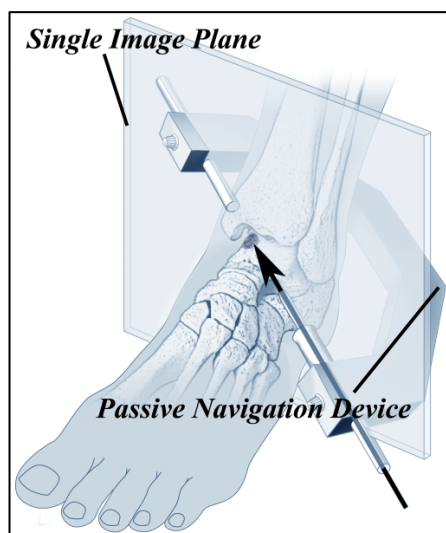
# Passive Navigation Concept for MR-assisted orthopedic Interventions - Evaluation in retrograde drilling of Osteochondrosis Dissecans (OD) of the Talus

C. J. Seebauer<sup>1</sup>, U. Teichgräber<sup>2</sup>, F. Wichlas<sup>1</sup>, T. Jung<sup>1</sup>, J. Rump<sup>2</sup>, R. Schilling<sup>2</sup>, T. Walther<sup>2</sup>, and H. J. Bail<sup>1</sup>

<sup>1</sup>Center for Musculoskeletal Surgery, Charité Universitätsmedizin Berlin, Berlin, Berlin, Germany, <sup>2</sup>Department of Radiology, Charité Universitätsmedizin Berlin, Berlin, Berlin, Germany

## Introduction:

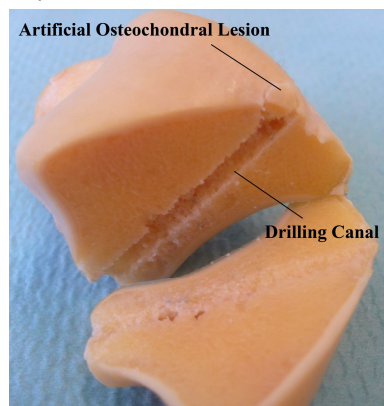
With the increasing role of MRI in diagnosis of musculoskeletal conditions, clinicians have explored the possibility of using MR guidance for musculoskeletal procedures. Open-configuration scanners provide access to patients during scanning procedure and therefore permit interventional procedures to be monitored with MRI [1]. Many navigation concepts are currently available. Active concepts like optical tracking and radiofrequency guidance require expensive hardware, instruction of surgical and non-surgical personal and are often limited in their use by image distortion [2]. We propose a passive, simple and inexpensive navigation concept, based on the cross-sectional nature of MRI navigation. Thus, no switching between orthogonal planes is necessary. Handling and accuracy of the device and passive navigation concept were evaluated in the retrograde drilling of OD of 10 cadaveric tali. Drilling under conventional X-ray guidance often leads to damage of the bone and cartilage, due to poor visualization and the complex anatomy of the ankle [3].



**Fig.2** Navigation concept

## Results:

The navigation concept was fast and safe in practice. The drilling device was easy to handle. Markers of the device were easy to visualize and ensured a fast navigation and drilling procedure (Fig.3). Saw cut specimens showed that the artificial lesion was hit in all cases with an accuracy of  $1.38 \pm 0.9$  mm (Fig.4). The time for predefinition of the coronal drilling plane on the user interface was  $3.6 \pm 0.3$  min, the time for exact drilling guide adjustment was  $3.7 \pm 0.7$  min and the time for drilling under MRI-guidance was  $1.5 \pm 1.8$  min. Due to the use of a low artifact titanium spiral drill and spin echo sequences, metal-related susceptibility artifacts were minimal and allowed exact assessment of anatomical structures and a safe drilling. Interactive PDW FSE was feasible for near real-time image acquisition and intervention.



**Fig.4** Saw cut specimen: all artificial lesions were hit

## Material and Methods:

Artificial osteochondral defects ( $\varnothing=4.5$ mm) were simulated in 10 human cadaveric specimens. All tests were performed on a 1.0T open MRI PANORAMA (Philips Medical Systems, Best, NL). For navigation, we used a custom-made MR-compatible drilling device (Fig.1). For visualization, it was marked with liquid filled tubes on its opposite ends. Navigation concept (Fig.2): The first step was to determine a single image plane in order to visualize the desired drilling direction and orientation. Second step: under interactive near real-time image acquisition, the drilling device was aligned to the selected plane using the filled markers as a reference. Third step: the two markers on each end of the drilling device were positioned in line with the osteochondral lesion. Fourth step: drillings were performed under interactive PDW FSE (TR:400ms, TE:8ms, FOV: 200x138, slice thickness: 3.5mm, 1.6s/image) control with a MR-compatible drilling machine (Invivo, Schwerin, Germany) with a 3.4mm titanium spiral drill. Saw cut specimens were taken and the distance of the drilling canal and the artificial OD lesion were measured.

## Conclusion:

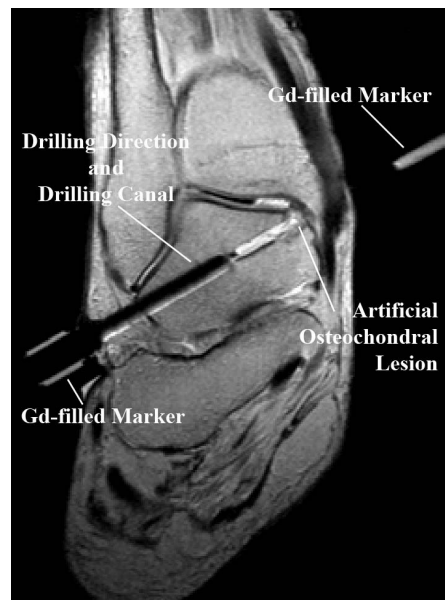
We are presenting a new, safe, passive and inexpensive navigation system for MR-assisted procedures. Of the possible uses, there appear to be many. Despite the navigation of MRI-assisted procedures like drilling of OD of the talus or knee, the utilization for drilling canal positioning for the ACL reconstruction of the knee, puncture or biopsy procedures of musculoskeletal conditions under MRI guidance are also imaginable. We conclude that our method is a viable alternative to conventional navigation concepts.

## Literature:

- [1] S.K.Koskinen, R.K.Parkkola, J.Karhu, M. E.S.Komu, M.J.Kormano; Orthopedic and interventional applications at low field MRI with horizontally open configuration; *Radiologe*; 37:819-824; 1997
- [2] M.Moche, R.Trampel, T.Kahn, H.Busse; Navigation Concepts for MR Image-Guided Interventions; *J.Magn.Reson.Imaging*; 27:276-291; 2008
- [3] Schumann L, Struijs PAA, van Dijk CN; Arthroscopic treatment for osteochondral defects of the talus; *J Bone Joint Surg*; 84-B:364-8; 2002



**Fig.1** Custom-made navigation device with opposite markers for visualization



**Fig.3** coronal PDW FSE image post drilling, the two markers are in plane and in line with the artificial OD