

# Diffusion-Weighted MRI (DWI) in Ovarian Masses: Value of DWI compared to T2 and T1-weighted MRI and Histopathological Findings.

N. Hottat<sup>1</sup>, T. Metens<sup>1</sup>, M. Kavac<sup>1</sup>, and C. Matos<sup>1</sup>  
<sup>1</sup>Radiology, Erasme Hospital, Brussels, Belgium

**Purpose :** Only a few studies on DW imaging of ovarian lesions have been reported (1-3), and there are few data available concerning epithelial lesions. Therefore the aim of our study is to determine the accuracy of diffusion weighted (DW) imaging in the characterization of ovarian masses in patients undergoing pelvic MRI.

**Materials and Methods:** 26 women (mean age: 45 years old) referred for the characterization of ovarian masses underwent conventional MR imaging on a 1.5T MR system (Philips Intera, Best, The Netherlands) using a 4-element SENSE body coil. T2-weighted, T1-weighted and DW MR Imaging (Single shot SE-EPI, b-values of 0 and 1000 s/mm<sup>2</sup>) were acquired. Three sets of MR images were separately read by one experienced radiologist: DW images alone, T2 and T1-weighted images and the whole MRI examination. Ovarian lesions were categorized as benign, borderline or malignant. All patients underwent surgical excision and MR results were compared to histopathological diagnosis. Moreover, ADC maps were calculated and ROI's were carefully drawn in order to include the entire lesion. In these ROI's the segmentation analysis of the ADC-value histograms provided the principal ADC components of each complex lesion, using FSL tool. Colored representations of the principal ADC components were then reconstructed upon the tumour ROI's.

**Results :** Histology confirmed 35 ovarian masses (all detected with MRI) : 26 benign (6 serous cystadenoma, 6 endometrioma, 4 dermoid cysts, 4 fibroma, 3 cystadenofibroma, 1 mucinous cystadenoma, 1 hemorrhagic corpus luteum cyst, 1 fibrothecoma), 8 malignant (6 ovarian carcinoma, 2 granulosa tumors) and 1 mild grade borderline mucinous tumor. Sensitivity and specificity for the diagnosis of malignant and borderline lesions were respectively of 100% and 77% with DW images, 100% and 81% with T2 and T1-W images and 100% and 85% with the whole set of images. False positive cases on DW images corresponded to 4 dermoid cysts, 1 fibrothecoma and 1 endometrioma; however 5 out of these 6 lesions were easily diagnosed on T2 and T1-W images. False positive cases on T2 and T1-W images corresponded to 4 benign epithelial tumors and 1 endometrioma (all negative on DW images). Interestingly all cystic lesions (n=10; 6 serous cystadenoma, 3 cystadenofibroma, 1 mucinous cystadenoma) without signal in b=1000 DW images were epithelial benign lesions. On the other hand, all malignant lesions showed a definite hypersignal in DW images with b=1000. Using ADC histograms, one to four principal components (cystic and solid portions) were identified in malignant masses. Fig.1 shows a suspicious heterogeneous ovarian mass in T2 and DW images: Fig.2 gives the corresponding ADC histogram: four different principal components are shown (ADC of 685.8 10<sup>-6</sup> mm<sup>2</sup>/s, 1270.0 10<sup>-6</sup> mm<sup>2</sup>/s, 1580.4 10<sup>-6</sup> mm<sup>2</sup>/s and 2091.9 10<sup>-6</sup> mm<sup>2</sup>/s). Histology revealed a serous cystadenocarcinoma constituted of solid, necrotic and cystic (fluid and viscous liquid) components.

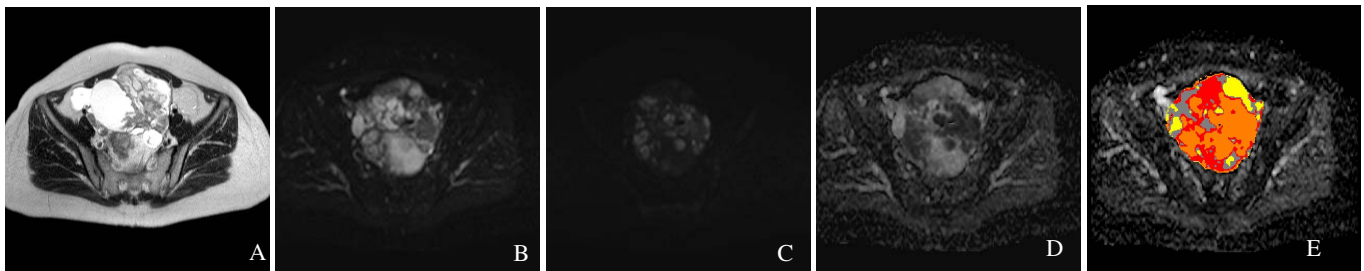


Fig.1: (a) T2-weighted image and (b) b=0 image show a complex mass that is hyperintense on the b=1000 DW image (c); the ADC map (d) confirms the multicomponent nature of the tumor, while the colored-ADC map displays the principal ADC components after segmentation

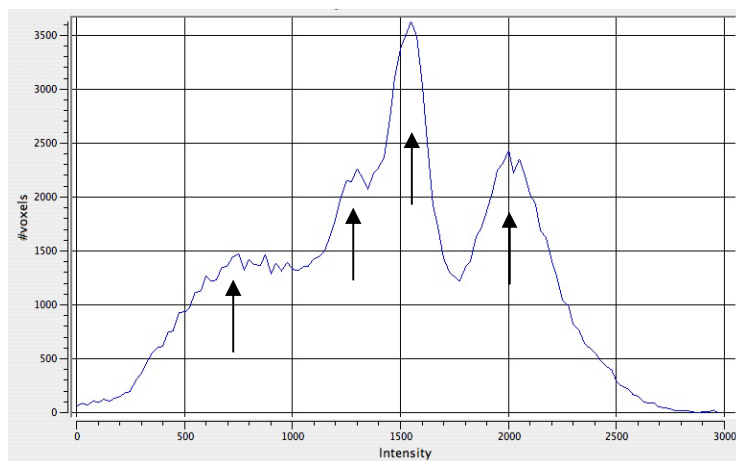


Fig.2: Histogram of the ADC value inside the heterogeneous tumor of Fig 1. The segmentation algorithm extracted 4 ADC principal values, corresponding to increased cellularity, necrosis and cystic components (arrows from left to right).

**Conclusion :** In our study, combining DW and conventional MR images increased the specificity for the characterization of ovarian lesions from 81 to 85%. Colored-ADC map of the lesions and dedicated histogram could be a useful tool in the evaluation of heterogeneous ovarian epithelial tumors.

**References :** (1) Katayama & al., JCAT 2002; 26 (2): 250-256 (2) Moteki & al., JMRI 2000; 12: 1014-101  
(3) Nakayama & al., JMRI 2005; 22: 271-278