

T_{1ρ} Relaxation Evaluation of Knee OA in a Guinea Pig Model

C. Wang^{1,2}, M. Fenty³, A. Borthakur³, G. Dodge⁴, and R. Reddy³

¹Bioengineering, University of Pennsylvania, Philadelphia, PA, United States, ²MMRCC, University of Pennsylvania, Philadelphia, PA, United States, ³Radiology, University of Pennsylvania, Philadelphia, PA, United States, ⁴Pediatrics, Thomas Jefferson University, Philadelphia, PA, United States

Objective: To establish an animal model of spontaneous osteoarthritis(OA) using T_{1ρ} MRI.

Introduction:

OA is a progressive and painful disease, and it is associated with tremendous individual and societal costs (1). T_{1ρ}-weighted magnetic resonance imaging(MRI) has shown promise as a diagnostic measure of early OA(2). The T_{1ρ} relaxation time has enhanced sensitivity to the interaction between bulk water molecules and components of extracellular matrix macromolecules such as proteoglycan(PG) in cartilage. The purpose of this study was to evaluate the efficacy of T_{1ρ} MRI in determining the OA changes in an animal model (Dunkin-Hartley guinea pig) of spontaneous OA.

Materials and Methods:

All animal-related experiments were reviewed and approved by our institute's animal use committee (IACUC). MRI was performed on the left knee joints of three 3-month-old and three 9-month-old guinea pigs in vivo on a Varian 9.4T horizontal-bore MRI scanner with a custom-built 2.5 cm diameter knee coil. Following localization of the joint with a standard gradient-echo protocol, a series of T_{1ρ}-weighted images were obtained in the coronal plane using a spin-lock prepared gradient-echo pulse sequence with the following parameters: TE/TR=8.04/1500ms, TSL (duration of spin-lock pulse)= 1, 10, 20, 30 and 40 ms, spin-lock frequency=1500Hz, slice thickness=1mm, FOV=3x3cm, Matrix=512x256. This protocol yields an in-plane resolution of 59x117 microns, with the highest resolution across the femoral-tibial cartilage. Cartilage was manually segmented from each, and the cartilage signal was fitted to an exponentially decaying function in order to obtain T_{1ρ} values on a pixel-by-pixel basis. After euthanasia, knee joints were decalcified using formic acid and processed for histology and immunohistochemistry. Safranin O, Masson's trichrome staining was performed on paraffin embedded sections. Immunohistochemistry was performed using aggrecan-specific antibody (Ab3778, Abcam) with detection using Envisions-HPR(Dako).

Results:

Typical T_{1ρ} maps overlaid on top of gray scale (t_{TSL}=1ms) images from a 9-month-old and a 3-month-old animal are shown in Figure 1. ROIs (shown as red rectangular boxes) were manually selected from the medial and lateral cartilage of both the 9-month-old and 3-month-old guinea pigs. The distribution of T_{1ρ} values from the medial cartilage ROIs are shown as histograms in Figure 2. The range of T_{1ρ} values is higher for the 9-month-old animal. In comparison, the medial cartilage ROIs of the 3-month-old has a smaller T_{1ρ} range, and the T_{1ρ} values are in general lower than those of the 9-month-old animals. Similar trends were observed for all three 9-month-old and three 3-month-old animals. After the animals were euthanized, the femoral-tibial joint was excised via sharp dissection. In Figure 3, cartilage stained for PG using Safranin O showed an overall reduction of staining in the medial side of the 9-month-old animal compared to that of the 3-month-old animal. Other signs of degeneration such as cell cloning, cartilage surface irregularities and cartilage thinning were only apparent in the 9-month-old animals and not the 3-month-old animals.

Conclusions:

T_{1ρ} is shown to be sensitive to knee OA in this spontaneous animal model. The protocol is sensitive to OA-like cartilage degradation, as confirmed by the histological results. We are in the process of imaging animals of multiple age groups to determine age-dependent T_{1ρ} changes in this guinea pig OA model. Although much work is needed to determine the precise correlations with cartilage changes at a molecular level and precisely what changes are most notably detected by this T_{1ρ} MRI technique, the results clearly show the feasibility of using T_{1ρ} MRI in this spontaneous OA guinea pig model in evaluating potential clinical therapies in longitudinal studies.

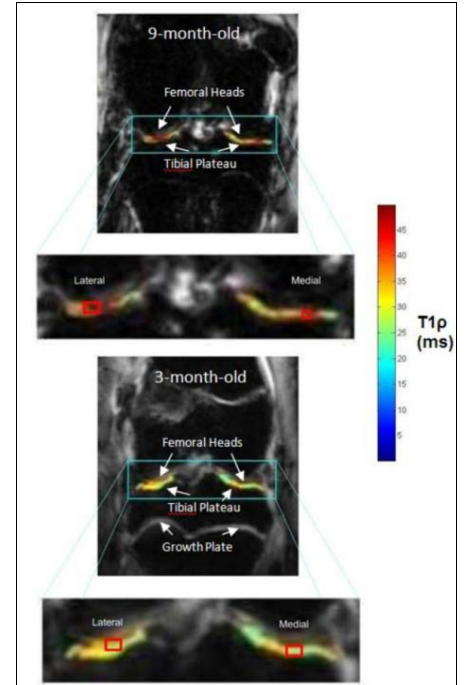


Figure 1. T_{1ρ} maps overlaid on gray-scale images for a pair of 9-month-old and 3-month-old animals.

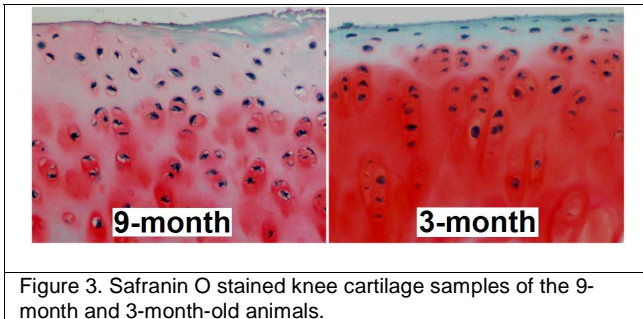


Figure 3. Safranin O stained knee cartilage samples of the 9-month and 3-month-old animals.

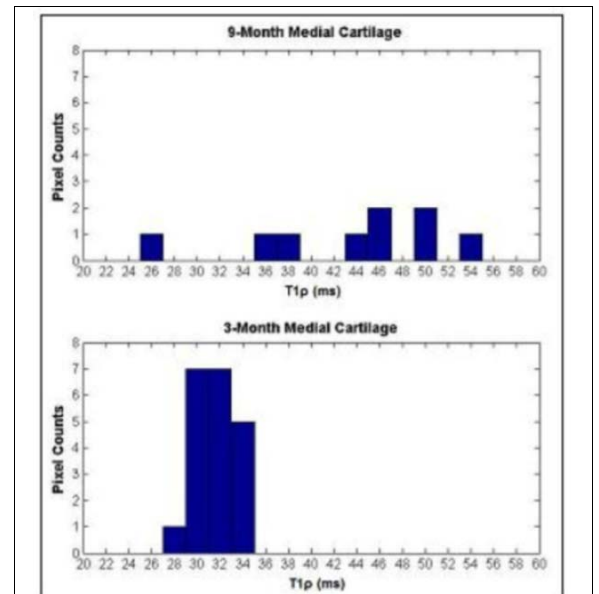


Figure 2. T_{1ρ} constant distribution in cartilage of 9-month and 3-month-old animals.

References:

1. Moskowitz RW. Osteoarthritis: diagnosis and medical/surgical management. Philadelphia: Saunders; 2001. xx, 674 p., [676] p. of plates p.
2. Borthakur A, Mellon E, Niyogi S, Witschey W, Kneeland JB, Reddy R. Sodium and T1rho MRI for molecular and diagnostic imaging of articular cartilage. NMR Biomed 2006;19(7):781-821.