

# Longitudinal diffusion tensor MR imaging study of radiation induced white matter damage in a rat model

S. Wang<sup>1</sup>, C. Tam<sup>1</sup>, E. Wu<sup>2</sup>, H-F. Lau<sup>2</sup>, D. Qiu<sup>1</sup>, L. Leung<sup>3</sup>, and P-L. Khong<sup>1</sup>

<sup>1</sup>Department of Diagnostic Radiology, The University of Hong Kong, Hong Kong, Hong Kong, <sup>2</sup>Laboratory of Biomedical Imaging and Signal Processing, Department of Electrical and Electronic Engi, The University of Hong Kong, Hong Kong, Hong Kong, <sup>3</sup>Department of Oncology, Princess Margaret Hospital, Hong Kong, Hong Kong

**Introduction:** Radiation-induced white matter (WM) damage is considered a major contributory factor of treatment-induced neurotoxicity prevalent among childhood cancer survivors who have undergone whole brain irradiation. We have shown in clinical DTI studies of childhood cancer survivors who received whole brain irradiation that WM FA is reduced, and that the reduction correlates with cognitive function (1). Using a rat model of radiation-induced WM injury (2), we aim to evaluate the longitudinal changes in DTI indices and its histological correlates.

**Materials and methods:** We irradiated the right hemibrain of twelve week old SD rats (n=37) with a single highly collimated (circular field of 12.5mm diameter) 6MV photon beam produced from a linear accelerator (Varian,USA) using 25Gy or 30Gy. Rats were scanned longitudinally at 2wks (n=17), 4wks (n=37), 8wks (n=29), 24 wks (n=19), 36 wks (n=19) and 48 wks (n=7) post radiation with DTI and T<sub>2</sub>WI using a 7T animal MRI scanner (Bruker, Germany) and a rat brain coil. Coronal sections were imaged from 2mm anterior to the corpus callosum to the end of the cerebrum. The following parameters were used for DTI: TR =3000ms, TE=32ms, Δ=15ms, δ=5ms, FOV = 30mm, thickness = 1mm, acquisition matrix = 256 x 256, b value =0 and 1000 s/mm<sup>2</sup>. T<sub>2</sub>WI images were obtained by using the following parameters: TR=11189ms, TE=20ms, FOV=25mm, acquisition matrix=128 x 128, slice thickness=1 mm. FA, trace, λ<sub>∥</sub> and λ<sub>⊥</sub> maps were created for quantitative analysis using DTIstudio v2.4 (Johns Hopkins University, U.S). Semi-automated method was applied for ROI analysis of the external capsule (EC) in both hemispheres. We randomly selected an FA image, transformed it to be as symmetrical as possible and used it as a template. Diffusion images were flipped and all the images including images either flipped or not flipped were affinely registered to the template using FSL (www.fmrib.ox.ac.uk/analysis). ROIs (Fig. 1; red and black area) were drawn on the template of the EC and mean FA, trace, λ<sub>⊥</sub> and λ<sub>∥</sub> of each rat were quantified on the registered images accordingly (Fig. 1). Rats were randomly selected for histological evaluation of WM injury after 4wks (n=9), 36wks (n=10) and 48wks (n=8). H&E, Luxol fast blue (LFB), neurofilament (NFL) and glial fibrillary acidic protein (GFAP) staining were applied to evaluate the WM morphological characterization, myelin, axon and glia cell. Extent of changes were graded as -, +, ++, +++.

**Results:** T<sub>2</sub>WI signal changes were found in the ipsilateral EC from 24wks onwards. Fig 2 shows DTI indices FA, trace, λ<sub>∥</sub> and λ<sub>⊥</sub> in the contralateral (white bar) and ipsilateral (black bar) EC from 2wks to 48wks after radiation (★, p<0.05). Earliest DTI changes of significantly decreased FA and λ<sub>∥</sub> were demonstrated at 4wks post radiation. Decreased λ<sub>∥</sub> in the ipsilateral EC remained significant in every time point from 4wks to 48 wks post radiation, and the reduction increased over time (from reduction of 2.5% at 2wks to 5.8% at 48wks). A slightly increased λ<sub>⊥</sub> in the ipsilateral EC was demonstrated at all time points but this did not reach statistical significance. Table 1 shows results of histological findings at 4wks, 36wks and 48wks post radiation. Decreased myelin and axonal density were only found at 48wks. H&E found slightly dilated vasculature at 48wks and necrosis at 36wks and 48wks. GFAP labeled astrocytic hypertrophy was demonstrated from 4wks and the extent increased at the later (36wks and 48wks) time points after radiation, and this corresponded to the reduction in λ<sub>∥</sub>.

Fig 1

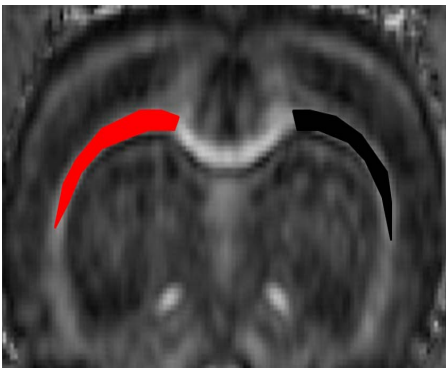


Fig 2

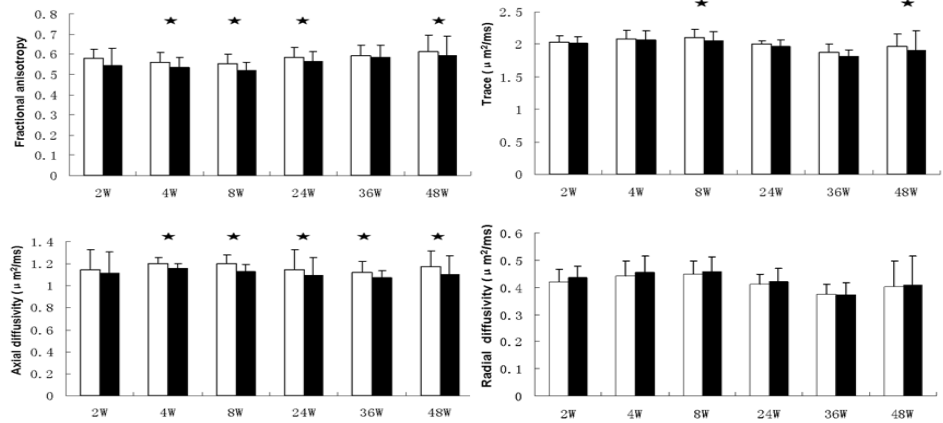


Table 1

	H&E Vascular dilation	H&E Cerebral swelling	H&E Vacuolation	H&E Necrosis	LFB Myelin Loss	NFL Axon decrease	GFAP Astrocytic hypertrophy
4w	-	-	-	-	-	-	+
36w	-	-	-	+	-	-	++
48w	+	-	-	+++	+++	+++	+++

**Conclusion:** Radiation induced WM injury is reflected by significant reduction in FA and λ<sub>∥</sub> and these changes can be detected as early as 4 weeks after injury, prior to T<sub>2</sub>WI signal changes. These changes correlate with astrocytic hypertrophy, suggesting that the relative abundance of astrocytes influence λ<sub>∥</sub> in the early changes of radiation induced WM injury, and this occurs before necrosis, axonal loss and demyelination. Therefore, FA and λ<sub>∥</sub> may be biomarkers for early detection of radiation induced WM injury.

**References:** (1) Khong PL et al. *J Clin Oncol*. 2006 20:884-890. (2) Kennedy AS, et al. *Invest Radiol* 1995;30:214-220.