

Whole heart coronary MR angiography acquired with 32-channel cardiac coils for the detection of coronary artery disease

M. Nagata¹, H. Sakuma¹, N. Ishida¹, T. Kurita², Y. Mikami¹, H. Nakajima², K. Onishi², M. Ito², and K. Takeda¹

¹Radiology, Mie university hospital, Tsu, Mie, Japan, ²Cardiology, Mie university hospital, Tsu, Mie, Japan

Purpose

Whole-heart coronary MR angiography (MRA) allows for noninvasive detection of coronary artery disease without use of contrast medium or exposing the patients to radiation. However, lengthy imaging time (>10minutes) and limited study success rate (<90%) are major limitations of whole-heart coronary MRA acquired with conventional cardiac coils. In the current study, whole heart coronary MR angiograms were acquired by using 32 channel cardiac coils and high SENSE factor. The imaging time, study success rate, image quality score and diagnostic accuracy of whole heart coronary MRA were evaluated in patients with suspected coronary artery disease.

Methods

We studied 32 patients with suspected coronary artery disease who were scheduled for elective X-ray coronary angiography (mean age 66 ± 15 , male: female = 24:8). Whole heart coronary MRA was acquired with a 1.5-T clinical MR imager equipped with 32-element cardiac coils and 32 channel receivers. Free-breathing whole heart coronary MRA was obtained by using a 3-dimensional, segmented steady-state free precession sequence with T2 preparation and radial k-space sampling (repetition time = 4.4ms, echo time = 2.2ms, flip angle = 80 degree, SENSE factor = 4, field of view = 300x300x130mm, acquisition matrix = 224x224x75, reconstruction matrix of 512x512x150). Images were acquired during a patient-specific time window in the cardiac cycle with minimal motion of the coronary artery that was determined on high-temporal resolution cine MRI. MRA data were acquired during diastole in 23 patients (averaged heart rate = 69.7 ± 11.5 beat/min, acquisition window = 92.1 ± 72.0 ms), and during systole in 9 patients (averaged heart rate = 80.7 ± 9.0 beats/min, acquisition window = 54.7 ± 22.0). Images were interpreted by 2 independent observers by using a sliding multiplanar reformat reconstruction method, and disagreement between 2 observers was settled by a consensus reading. All patients underwent conventional X-ray coronary angiography within 2 weeks from coronary MRA. X-ray coronary angiograms were analyzed by a separate blinded reviewer. Significant coronary artery disease was defined on X-ray coronary angiography as a diameter reduction of $\geq 50\%$ in coronary arteries with a reference of ≥ 2 mm.

Results

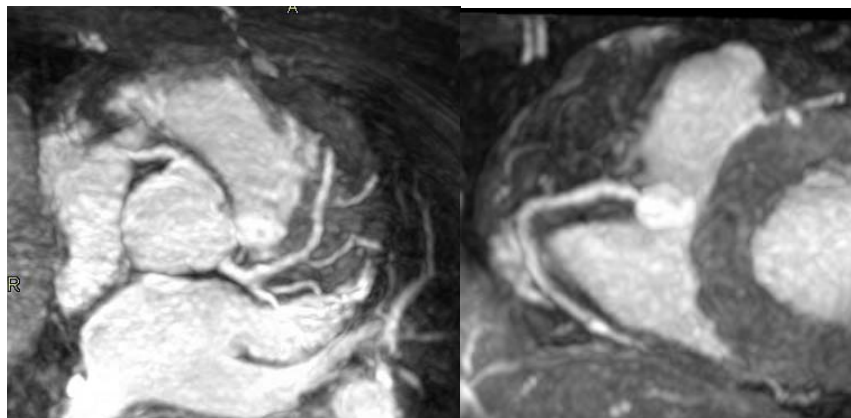
Acquisition of whole heart coronary MRA was successfully completed in 32 (100%) of 32 patients. The averaged imaging time with 32-channel cardiac coils was 6.2 ± 2.8 min, which was approximately half of that with 5-channel cardiac coils. The averaged image quality score was 4.6 ± 0.2 with 32 channel coils and high SENSE factor of 4, which was approximately equal to or slightly better than that (4.5 ± 0.2) by 5 channel coils and SENSE factor of 2. On X-ray coronary angiography, significant narrowing in the coronary artery was found in 19 of 32 patients (59%). On a patient-based analysis, the sensitivity, specificity and accuracy of whole heart coronary MRA was 79% (15/19), 92% (12/13) and 84% (27/32), respectively. When all subjects enrolled were analyzed regardless of study success, the overall sensitivity of whole heart coronary MRA with 32 channel cardiac coils was substantially higher than that with 5 channel coils (79% versus 68%¹)

Conclusions

Use of 32 channel cardiac coils and high SENSE factor allows for acquisition of whole heart coronary MRA in a considerably reduced imaging time (6.2 ± 2.8 min) and with high study success rate (100%), when compared with 5 channel coils¹ (imaging time of 12.9 ± 4.3 min and success rate of 86%). High study success rate achieved by 32 channel coils substantially improved overall sensitivity of coronary MRA in detecting patients having CAD when all subjects who underwent MRA were evaluated.

Reference

- 1) Sakuma, et al. J Am Coll Cardiol 2006; 48: 1946



Whole heart coronary MR angiography in 87-year-old woman.
Acquisition time was 1 min 10sec with 32-channel coils.