

Complex Constant Phase Statistical Model Reduces Venous Contributions to BOLD Cortical Activations in the Visual Cortex

A. S. Nencka¹, E. S. Paulson¹, and D. B. Rowe¹

¹Department of Biophysics, Medical College of Wisconsin, Milwaukee, WI, United States

Introduction: It is well known that the blood oxygen level dependent (BOLD) contrast used in fMRI is sensitive to the capillaries where the blood oxygenation change occurs and the down-stream draining veins. Although the capillaries are located at the locus of the functional activity, down-stream draining veins may contribute non-negligible effects to delocalized BOLD contrast activations several millimeters away from the region of activation.¹ However, such veins are likely to contribute a net phase to the observed signal because of the blood oxygenation level dependent resonance frequency of intravascular spins. To reduce the contribution from such draining veins in cortical activation studies, Menon introduced the phase regressor method in 2002 to discount BOLD activations which arise in voxels which contain draining veins by regressing phase-associated magnitude changes from all time series.² In 2004 Rowe and Logan introduced the complex-constant phase method which can be used to reduce the activation statistics in voxels which present non-constant phase time series.³ Both methods have been claimed to reduce draining vein activations.^{2,4,5,9} Here we present activations from each of the methods along with a venogram of the visual cortex for a flashing checkerboard visual stimulus.

Methods: Two subjects were imaged with a 3.0 T General Electric Signa LX scanner. The subjects were imaged using a susceptibility weighted high resolution flow compensated gradient recalled echo anatomic scan. The parameters for this venographic pulse sequence included: TE/TR 28/46 ms, flip angle 20°, field of view 24×18×6 cm³, acquisition matrix 512×256×60. Venograms were created by creating minimum intensity projections through multiple slices.⁶ The subjects then performed a blocked design visual task of fixation on a mark and observing a checkerboard flickering at 4 Hz. The task included an initial rest of 20 seconds followed by eight epochs of 16 seconds of task and 16 seconds of rest. The parameters for this functional experiment included: TE/TR 45.3/2000 ms, flip angle 77°, field of view 24×24 cm², acquisition matrix 96×96, slice thickness 2.5 mm. Thus, the visual cortex was imaged with isotropic (2.5 mm)³ voxels. Activations were computed with the standard magnitude-only general linear model, phase regressor model, and complex constant phase model. Signed *z*-statistics were generated with an $\alpha=0.05$ slice-wise Bonferroni adjusted threshold.

Results: Figure 1 illustrates the results in one slice. Figure 1 (a) is a venogram with a minimum intensity projection through the shown functional slice and its neighboring slices. Figures 1 (b), (c), and (d) illustrate the magnitude-only, phase regressor and complex constant phase model activations. Venous activations are indicated with the identically located arrows.

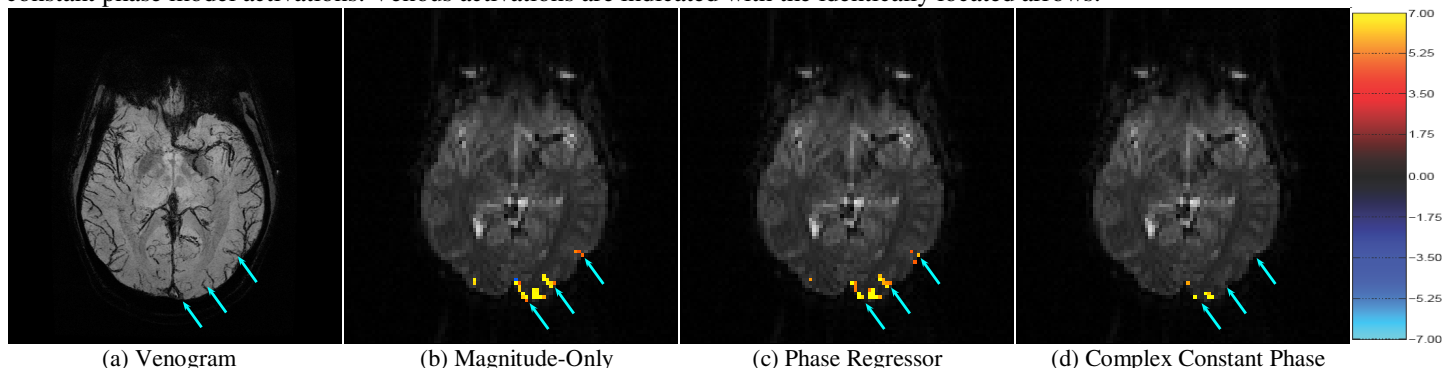


Figure 1: (a) Minimum intensity projection of the venogram through the functional slice and its two neighboring slices. (b) Magnitude-only activations from the visual task include regions of activation with a high correspondence to draining veins (arrows). (c) Phase regressor activations reduce the statistical significance of the draining veins while not excluding them from activations. (d) Complex constant phase activations exclude the obvious draining vein activations while preserving a cluster of voxels in which no large draining veins are observed.

Discussion: The strong correlation of magnitude-only BOLD activations with large draining veins is in agreement with many studies.⁷ Only one cluster of activations in the illustrated slice does not closely correspond to the hypo-intense signal of the draining veins in the venogram. This is the cluster between the center and left arrows, and it is thus believed to be parenchymal in origin. This cluster is preserved with all activation statistical methods. Activations along draining veins identified in the venogram are indicated by the blue arrows in the magnitude-only activation image, and the identical arrows in the other images. It is clear that the phase regressor method yields activation statistics which are reduced in magnitude but which are still above threshold in these veins. However, the complex constant phase method finds vastly reduced venous activations. It is likely that the marked difference between the complex constant phase and phase regressor activations is a result of multiple factors. Errors in the phase regression of the phase regressor method may lead to its sub-optimal draining vein removal.⁸ Non-task related phase changes may be responsible for the decreased volume of parenchymal activation found by the complex constant phase method. This could also be from un-resolved, well-oriented draining veins within the volume.

References: (1) Turner, R. NIMG 16:1062-1067, 2002. (2) Menon, R.S. MRM 47:1-9, 2002. (3) Rowe, D.B. and Logan, B.R. NIMG 23:1078-1092, 2004. (4) Nencka, A.S. and Rowe, D.B. Proc. ISMRM 13:495, 2005. (5) Rowe, D.B. and Nencka, A.S. Proc. ISMRM 14:2834, 2006. (6) Reichenbach, J.R. et al. Radiology 204:272-277. (7) Duong, T.Q. et al. MRM 49:1019-1027. (8) Nencka, A.S. and Rowe, D.B. Proc. ISMRM 14:3269, 2006. (9) Nencka, A.S. and Rowe, D.B. NIMG 37:177-188, 2007.

Acknowledgments: Supported in part by NIH EB000215, AG020279, MH019992.