

# Systemic reactivation of a focal MOG-EAE lesion in rat brain revealed by MRI and immunohistochemistry

S. Serres<sup>1</sup>, Y. Jiang<sup>2</sup>, D. Tyler<sup>1</sup>, D. Anthony<sup>2</sup>, and N. Sibson<sup>1</sup>

<sup>1</sup>DPAG, University of Oxford, Oxford, United Kingdom, <sup>2</sup>Pharmacology, University of Oxford, Oxford, United Kingdom

**Background:** Multiple sclerosis (MS) is a neurodegenerative disease characterised by a chronic inflammatory disorder associated with demyelination and axonal injury. The majority of MS cases display a relapsing-remitting form of disease leading to a secondary progressive phase which is non-relapsing. It is probable, but as yet unproven, that environmental risk factors such as viral and bacterial infections play a role during the relapse-remitting phase of the disease. The aim of this work, therefore, was to discover whether a systemic infection can reactivate a quiescent MS-like lesion in the brain.

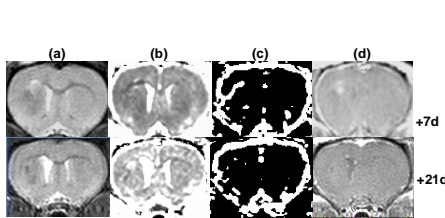
**Methods:** A focal EAE-MOG lesion was induced in Male Lewis rats by subcutaneous injection of MOG peptide (35-55) followed three weeks later by intracerebral injection of cytokines into the left hemisphere; thus targeting the resultant EAE lesion to this site. Four weeks later, the animals were challenged by i.p injection of lipopolysaccharide (LPS) to mimic bacterial infection. Both the initial development and resolution of the focal EAE-MOG lesion, and the subsequent reactivation of the lesion by LPS was studied serially by MRI and at selected time points using immunohistochemistry.

- Animals underwent MRI under anaesthesia (1-2% isoflurane in 70% N<sub>2</sub>O:30% O<sub>2</sub>) in a 7T horizontal bore magnet.
- MRI:** T1- (pre- and post-gadolinium) weighted images (TR=500ms; TE=20ms), T2-weighted images (TR=3s; TE=0.016s), and apparent diffusion coefficient (ADC) trace map (TR=2s, TE=36ms;  $\delta/\Delta=12/17$ ms; b=125, 500, 1000 smm<sup>-2</sup>) were acquired. Cerebral blood volume (CBV) maps were obtained from a time series of 40 FLASH images (TR=0.02sec; TE=0.01msec; flip angle 20°) during bolus injection of contrast agent and tracer kinetic analysis. *Ex vivo* 3D gradient echo images (TR=30ms, TE=10ms; flip angle 10°; scan time=14hrs) of brains were obtained on a 500MHz vertical bore system.
- Immunohistochemistry:** Macrophages were identified using the mouse monoclonal antibody ED1 (Serotec) and the number of ED1-positive cells counted. Demyelination was identified by the loss of MBP staining (Serotec) in the corpus callosum.

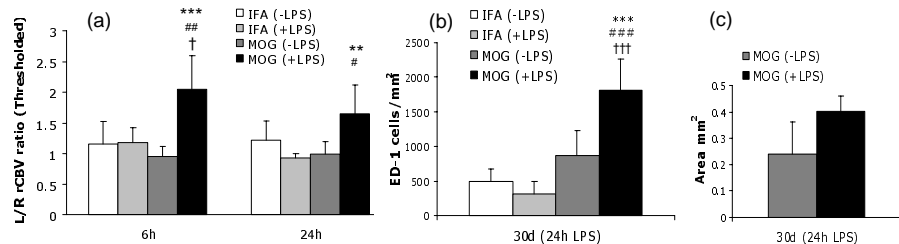
**Results:** (i) **Lesion development and resolution.** As shown in Figure 1, T2-weighted images (a) exhibited a marked hyperintense signal within the corpus callosum at the intracerebral injection site 7 days after intracerebral injection, which had disappeared at 14 days post-injection although incomplete recovery of the baseline signal from the corpus callosum was observed. Associated with these changes, a progressive increase in ventricle size was evident in the lesioned hemisphere. In some animals an area of signal reduction was seen in the striatum below the injection site. Apparent diffusion coefficient (ADC) trace maps (b) show the development and resolution of an area of decreased ADC within the corpus callosum at the injection site, surrounded by an expanding area of increased ADC. In thresholded rCBV maps (c), an increase in rCBV is observed in the injected hemisphere up to 7 days after intracerebral injection, which subsequently resolves. Post-contrast T1-weighted images (d) were acquired to ascertain BBB integrity and show gadolinium enhancement in the lesion up to 7 days post-injection, which resolves thereafter.

(ii) **Reactivation.** As shown in Figure 2, the induction of a systemic inflammatory response with LPS challenge resulted in a new increase in the left/right CBV ratio determined by MRI in the region surrounding the lesion, at both 6 and 24hrs post-LPS injection (a). Immunohistochemically, an increase in macrophage activation (b) and demyelination (c) was also observed at these time points. Subsequently, the use of high-resolution 3D MR microscopy and USPIO injection enabled us to determine that the origin of the renewed macrophage activation was, in part, new macrophage infiltration as shown in Figure 3.

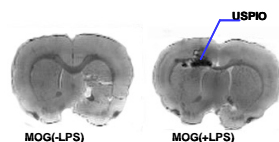
**Conclusion:** This work demonstrated that the reactivation of inflammatory processes within a previously quiescent CNS lesion can be induced by a systemic inflammatory response in a clinically-relevant model of MS. These findings have important implications for the management and treatment of patients with MS.



**Figure 1:** MRI images acquired at days 7 and 21 after induction of EAE MOG lesion



**Figure 2:** (a) MOG animals challenged with LPS showed a significant increase in rCBV in the zone surrounding the lesion at 6 and 24 hrs. (b) In correlation, a significant increase of ED1 positive cells was observed 24 hrs after LPS injection revealing macrophage activation. (c) Also, an increase of myelin loss is observed. \*, #, † denote significant differences between MOG (+LPS) and MOG (-LPS), or IFA (+LPS), or IFA (-LPS) respectively. \*, #, †  $P < 0.05$ ; \*\*, ##, ††  $P < 0.01$ ; \*\*\*, ###, †††  $P < 0.001$ .



**Figure 3:** The origin of the macrophage activation was investigated by injecting USPIO (ultra small particle of iron oxide) i.v. This particle can be phagocytosed by macrophages in the blood and detected in the brain after macrophage infiltration as a reduction in signal intensity in T2-weighted images.