

MOUSE BRAIN DIFFUSION TENSOR MAGNETIC RESONANCE IMAGING (DT-MRI):ASSESSMENT OF DEMYELINATION AND RECOVERY

L. A. Harsan¹, D. Paul¹, D. von Elverfeldt¹, J. Steibel², J. Hennig¹, and S. M. Ghandour²

¹Department of Diagnostic Radiology, Medical Physics, University Hospital Freiburg, Freiburg, Germany, ²Laboratoire d'Imagerie et Neurosciences Cognitives, UMR7191, Université Louis Pasteur, Strasbourg, France

Introduction:

Multiple Sclerosis (MS) is a chronic, inflammatory demyelinating disease of the central nervous system (CNS). Several animal models that mimic the human disorder were described in the literature (1). Long-term 0.2% cuprizone feeding in mice produces an interesting model of MS that underlies progression of acute demyelinated lesions to chronic state (2). In the present study, brain noninvasive in vivo DT-MRI was employed to quantify the demyelination extent in male and female cuprizone treated mice. The potential of a thyroid hormone (T3) based therapy, applied to induce recovery in the chronic demyelinated mouse brains was further assessed in vivo in a longitudinal study. The radial (D_{\perp}) and axial (D_{\parallel}) diffusion coefficients as well as the fractional anisotropy (FA) maps were compared to the histological data.

Materials and Methods:

Three groups of 8-week old C57BL/6 mice were used for DT-MRI exam at different time points (week 0, 12, 12+3, 12+6, 12+12) (Fig 1). A spin-echo imaging sequence modified by adding the Stejskal-Tanner diffusion gradient pair was used to image the brains in a 4.7T scanner for small animals. Brain sagittal slices of 0.5mm (FOV of 20x20 mm², data matrix 256x256, zero-filled to 512x512) were acquired using the following protocol: TR=1.5 s, TE=35 ms, Δ = 21.7 ms, diffusion gradient duration (δ) = 5.6 ms and a b factor of 865s/mm². Diffusion gradients were applied along 6 non-collinear directions.

The protocol was further improved for tractography using a 9.4T small bore animal Scanner (Biospec 94/20, Bruker, Ettlingen, Germany) to obtain DT-EPI data, with diffusion gradients applied in 15 non-collinear directions and a b factor of 1000s/mm². D_{\perp} and D_{\parallel} as well as FA maps were generated and statistical analysis among groups performed.

Results and Discussion:

DT-MRI data showed distinct changes in the mouse brains from different groups corresponding to their treatment.

12 weeks of cuprizone administration resulted in greatly increased values of D_{\perp} , related to the myelin layers degeneration and oligodendrocytes loss. FA values in the mice corpus callosum are reduced after cuprizone demyelination (Fig 3). This DT-MRI and histological pattern is maintained in the group of mice not receiving hormonal therapy.

T3 treatment induces a consistent remyelination of the corpus callosum as well as an enhanced oligodendrogenesis. The progressive recovery pattern of D_{\perp} (Fig 2) and FA (Fig 3, w12+12) values after T3 administration is similar with the remyelination profile observed in

histology. The present study successfully exploited the sensitivity of the DT-MRI technique for longitudinal following of demyelination and for assessing the T3 induced recovery.

References:

1. Lassmann H. Rev Neurol. 2007, 163(6-7):651-5.
2. Mason, J.L., Toews, A et al., Am. J. Pathol. 2004, 164, 1673-1682.

Fig 1. Experimental protocol

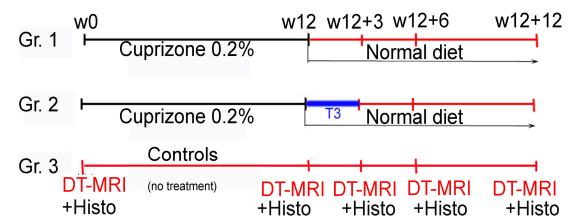


Fig 2. Radial diffusion in the corpus callosum

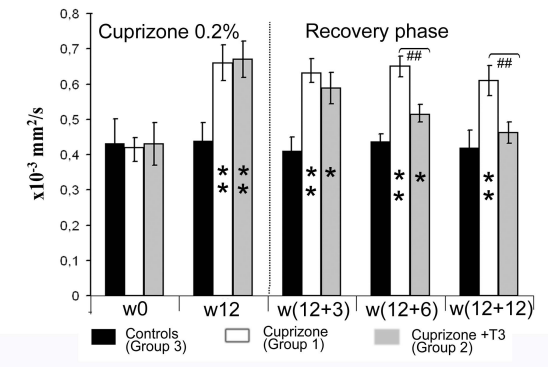
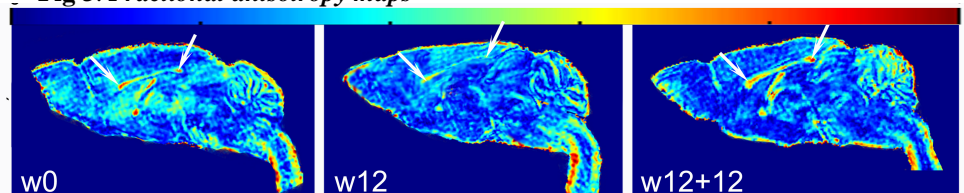


Fig 3. Fractional anisotropy maps



w0: FA map of a mouse brain before cuprizone treatment. **w12:** Low values of FA are observed in the corpus callosum after cuprizone induced demyelination. **w12+12:** Recovery of the FA values after T3 based therapy