

Automated Tracking of a Passive Endomyocardial Stiletto Catheter with Dephased FLAPS MRI: A Feasibility Study

I. Koktzoglou^{1,2}, S. A. Tsiftaris³, S. Zuehlsdorff⁴, D. Li², A. K. Katsaggelos³, and R. Dharmakumar²

¹Department of Radiology, Evanston Northwestern Healthcare, Evanston, IL, United States, ²Department of Radiology, Feinberg School of Medicine, Northwestern University, Chicago, IL, United States, ³Department of Electrical and Computer Engineering, Northwestern University, Evanston, IL, United States, ⁴Siemens Medical Solutions, Chicago, IL, United States

Introduction: Direct intramyocardial therapies aiming to mitigate the adverse effects of myocardial infarction may benefit from interventional procedures guided by magnetic resonance (MR) imaging. Although interventional MR approaches using active, circuit-bearing, devices are considered to be the method of choice, potential tissue heating and altered mechanical properties are their limitations. Methods that have the capacity to visualize ‘passive’ MR-compatible devices that lack circuitry may overcome these obstacles. Recently, FLAPS (Fast Low Angle Positive Contrast with Steady-State Free Precession Imaging), a real-time positive contrast method that preferentially enhances the MR signal of off-resonant spins (FLAPS), was used to visualize the passage of a passive intramyocardial needle (PIN) through the aorta and into the heart of a live swine (1,2). Dephased FLAPS (dFLAPS), a variation of FLAPS is well-suited for interventional applications requiring thick imaging slices (3). A combined implementation of dFLAPS imaging with image processing strategies that track the needle’s location in the image domain throughout the MR procedure has the potential to improve device visualization and *in vivo* guidance. The purpose of this work was to test the feasibility of automated off-resonance MRI-based tracking of a passive intramyocardial needle in a realistic phantom of the thoracic aorta.

Methods: *Experimental Setup & Imaging:* A 7F steerable endomyocardial stiletto catheter (Boston Scientific, USA) commonly used for delivery of therapeutic agents was fitted with a MR compatible, 22-gauge, 15 mm (full length) and 8 mm (exposed length) needle (Lufkin, E-Z-EM, USA). A realistic phantom of the thoracic aorta (Elastrat; Switzerland) (Figure 1) was filled with water doped to mimic the relaxation characteristics of blood and placed in a 1.5 Tesla Siemens Sonata scanner. The catheter was advanced through the phantom while continuous MR imaging was performed using a dFLAPS sequence. Two overlapping, orthogonal dFLAPS slices acquired in an interleaved fashion were used to extract the location of the needle. Imaging parameters were: 30 x 30 cm field-of-view, 10 cm slice thickness, 192 x 192 matrix, TR/TE = 2.8/1.4 ms, frame rate ~ 2 Hz.

Needle Tip Tracking Algorithm: Although in practice a real time system will be used, in this case, all slices were processed offline. Two orthogonal MR images, $O(x,y)$ and $E(z,y)$, of the phantom were used simultaneously to track the needle tip with an image processing algorithm (implemented in MATLAB.) The algorithm took input of the initial location of the needle (regions of positive contrast) from the first frame and detected the needle in subsequent frames using a template matching method. The template matching methodology used information from the previous frame and allowed for rotation and scaling to adapt to the dynamic MR footprint of the needle. In cases where the needle could not be tracked within a search window, the user was prompted to reinitialize the needle position. (In practice, this simulates situations where the needle is occluded or lost and hence the user will have to back-track the catheter to relocate/recover its position.) A Kalman filter was used to smooth the data and all observations were combined to improve the accuracy of the needle’s position.

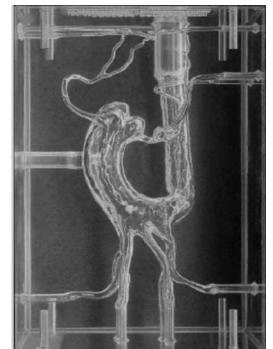


Figure 1. Realistic phantom of a thoracic aorta used in experiment.

Results: Figure 2 shows the needle tracking results obtained from bi-plane dFLAPS images by means of a deformable template matching image processing algorithm. Both the point-based and smoothed trajectories of the needle movement within the aortic phantom are shown superimposed onto the orthogonal MR images.

Discussion & Conclusions: The feasibility of image-based tracking of a passive intramyocardial needle with dFLAPS was demonstrated in a phantom of an aorta. Although image processing was performed retrospectively in this study, given the real-time capacity of the template tracking method, it should be readily adaptable for prospective guidance. Future studies need to extend this work to *in vivo* conditions to assess the capacity of the technique within the heart and aorta.

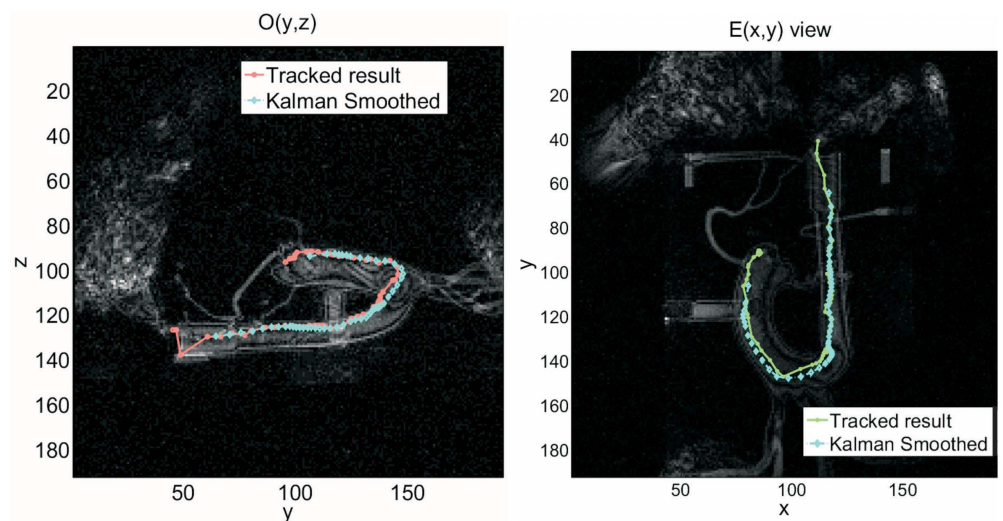


Figure 2. Computer tracked trajectories of the passive intramyocardial needle as seen on orthogonal dFLAPS views.

References: (1) Dharmakumar et al. *Phys Med Biol.* 51: 4201-4215 (2006); (2) Dharmakumar et al. *Proceeding of ISMRM 2007*, p. 493 (3) Koktzoglou et al. *Phys Med Biol.* 52:N277-N286 (2007)