

One Touch Imaging for Improved Cardiac Workflow

R. D. Darrow¹, V. Vaidya², A. Govenkar³, R. Mullick², and T. K. Foo¹

¹MRI, GE Global Research, Niskayuna, New York, United States, ²Imaging Technologies, GE Global Research, Bangalore, India, ³Extenprise, Inc., Pune, India

Introduction

Cardiac MR examinations are complicated procedures, with complex workflows that require skilled operators. A critical component of the cardiac examination is the ability to perform the necessary scout scans to prescribe the short and long axis views in a minimal amount of time. The speed to arrive at the needed cardiac scan planes is directly proportional to the skill of the operator. The conventional approach is to perform a series of successive oblique scans, starting from an axial or sagittal view, culminating in the short axis plane. The 2-chamber and 4-chamber long axis planes are then prescribed from the short axis view. Any error or variability in any step of the procedure will result in non-ideal final cardiac scan planes. This variability can lead to a lengthy examination and inconsistencies in the diagnostic quality of the cardiac examination. The goal then is to have a computer-driven algorithm to make the necessary computations. Previous work has focused on the algorithm development [1-2] but has not integrated the computation with image acquisition. We demonstrate a method by which requisite cardiac scan planes can be computed from ungated 3-plane localizers automatically, and seamlessly integrated with normal scanning without operator intervention. This allows a protocol-driven cardiac examination to be completed by less skilled MR technologists, providing greater consistency and reproducibility in the cardiac exam.

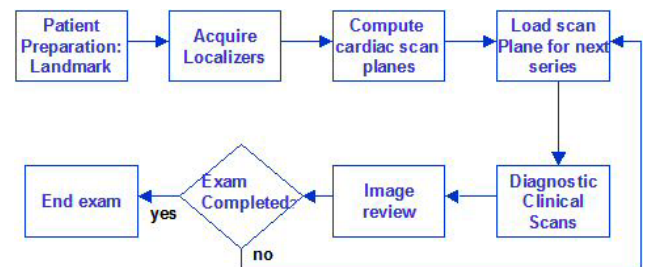


Figure 1: One-Touch Cardiac workflow

Methods

All data were acquired on a 1.5 T GE CV/i scanner with an 8-element cardiac phased array coil. Custom user interface (UI) and scan process were constructed allowing full or semi-automated cardiac scanning. After obtaining written informed consent, healthy volunteers were scanned using the workflow shown in Figure 1. The entire procedure was automated and initiated by a single button push. The short and long axis scan planes were computed from 3-plane ungated free-breathing FIESTA localizer scans [3]. As the spatial coverage of the localizers was sufficiently large to cover the heart in every volunteer, preset L/R, A/P, and S/I localizer extents was used. On completion of the localizer scans, the feature recognition algorithm [3] was kicked-off to compute the cardiac views. This algorithm was previously validated against manually prescribed scan planes with a mean variation of less than 6°. This algorithm fits the elevation and azimuth of the left ventricle orientation using feature recognition techniques, and proceeds to determine the short axis plane using anatomic priors. The computed scan plane coordinates were then automatically fed to the next scan in the protocol flow to acquire gated, breath-held 2D FIESTA CINE images in multiple slice locations covering the entire left ventricle.

Results

Figure 2 shows a screenshot showing the UI and an acquired mid-ventricular short-axis image. Overall, the acquisition of the 3-plane localizers took approximately 2 minutes. The time for the unoptimized code to compute the short axis plane was another 3 minutes on the MR scanner. On the average, after only 5 minutes from the start of the study, the primary high quality breath-held 2D FIESTA CINE acquisitions in multiple short axis views began. The number of short axis slice locations varied with the individual anatomy (8-12 slices) and was completed in under 10 minutes.

Discussion and conclusions

We have implemented a robust, efficient and rapid system for automated short-axis acquisitions by seamlessly integrating a feature recognition algorithm into the scan workflow that computes the cardiac scan planes. The computational time of about 3 minutes can be aggressively reduced to

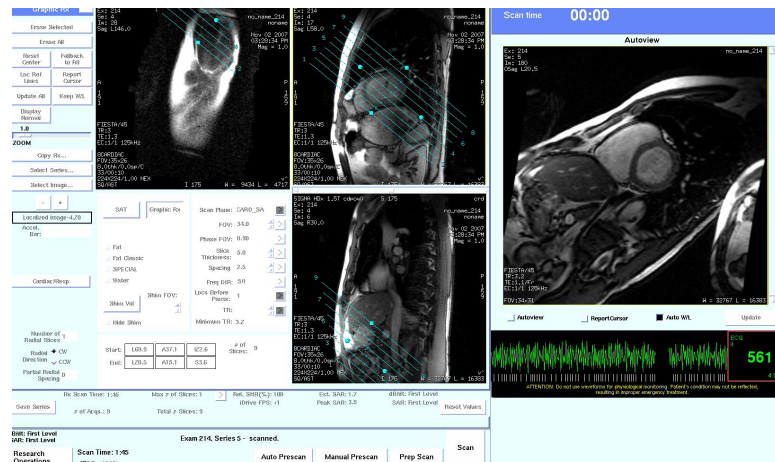


Figure 2: Screenshot showing the automatically prescribed scan planes placed on the 3-plane localizers and the resultant short axis view in a volunteer.

less than 30 sec by code optimization. Further optimization in the 3-plane localizer allows the entire process, from localizer scans to computation of scan planes to be reduced from 5 min to under 2 min. A typical breath-held short axis CINE series can thus be acquired in about 7-8 min with minimal or no operator intervention. This workflow optimization leads to the ability to achieve cardiac scans of greater consistency, especially in small community settings where highly skilled MR cardiac technologists are not easily available. We plan to extend this work in progress to encompass additional elements of an integrated exam, including HLA, VLA views, and coronary artery views for RCA, LAD/LM, LCx and RAO.

References

1. Lelieveldt BPF, van der Geest RJ, et al. Radiology 2001; 221: 537-42.
2. Jackson CE, Robson MD, et al. Computerized Medical Imaging and Graphics 2004; 28: 411-8.
3. Dwivedi S, Vaidya V, et al. Proceedings of ISMRM 2007. p. 3863.