

High Resolution Functional MRI Imaging of Material-Specific Encoding in the Head, Body and Tail of the Hippocampus

W. Ringe¹, K. Gopinath², S. Cheshkov², S. Sarkar², R. Briggs², and R. Haley³

¹Department of Psychiatry, UT Southwestern Medical Center, Dallas, TX, United States, ²Department of Radiology, UT Southwestern Medical Center, Dallas, TX, United States, ³Department of Internal Medicine, UT Southwestern Medical Center, Dallas, TX, United States

Introduction: We previously reported [1] specific and overlapping representations in the medial temporal lobe and related structures during encoding of different types of verbal and nonverbal stimuli (i.e., words, nameable objects, faces and nature scenes). While most other investigations to date have not offered enough spatial resolution to detect and differentiate material-specific encoding activation in the various subregions of the MTL [2-8], we presented evidence that a limited FOV high-resolution (1.56 mm X 1.56 mm X 2 mm) fMRI scanning sequence could be particularly useful in the study of parcellation of memory processes in the subdivisions of the MTL. The purpose of the current study is to extend previous findings to an examination of hippocampus-specific activity during encoding of each material type and to report encoding activation that is greater than the effects of basic visual processing of the various material types.

Methods: Seventeen healthy subjects (10 F, 7 M, mean age 32.4 yrs, all R-handed, mean education 17 yrs) participated. Written informed consent was obtained for all subjects. Data were analyzed from encoding portions of a material-specific memory fMRI task. The task was presented visually in an event-related design in which stimulus presentation trials were alternated with scrambled picture trials. Stimulus types were counterbalanced across runs and included words, objects, faces and nature scenes. Subjects were instructed to learn each stimulus and then probed during a recognition trial (results reported elsewhere) during later scanning runs. Additionally, one image of each material type was shown repeatedly and used as a material-specific visual processing control condition. fMRI images were acquired on a 3T Siemens Trio scanner with a 12-channel receiver coil using a high-resolution EPI sequence: TR/TE/FA = 2000 ms/ 24.7 ms/ 90°; FOV = 100 mm; 64 x 64 matrix, 33 2 mm coronal slices covering the anterior-to-posterior extent of the MTL, 1.56 mm x 1.56 mm x 2.0 mm voxels. A high-resolution T1-weighted MPRAGE scan (matrix size = 160x256x256 with resolution 1x1x1 mm³, TI/TR/TE = 900/2250/2.97 ms, flip angle = 9°) was acquired for anatomic reference. The observed fMRI voxel time-series was modeled as the convolution of the four material-specific learning (LEARN) and repeating (REPEAT) stimulus vectors and constrained 2-parameter [9] impulse responses (IRs). Voxelwise maps of IR amplitude (as a percentage of the estimated time-series baseline) were constructed. These functional activation maps were warped to Talairach space, resampled at a 1 mm³ resolution, and subsequently spatially smoothed with a Gaussian kernel (FWHM = 3 mm). Within-group ANOVA was performed to assess the significance of activation for the four different material types as well as the between-type contrasts of LEARN>REPEAT for each type of material. Analysis was focused on the bilateral hippocampus using a region specific mask with a model-based segmentation/registration tool. The t-maps of condition-level activations were further clustered ($|t_{16}| > 1.9$; cluster volume threshold 50 μ l; corrected $p < 0.02$). AFNI and FSL software packages were used for data analysis.

Results: As can be seen in the figure, different areas of hippocampal activation were observed during the LEARN>REPEAT contrast for each of the four material types. Words (red) activated bilateral (left greater than right) hippocampal head, and left hippocampal body and tail. Pictures of nameable objects (yellow) activated bilateral (right greater than left) hippocampal head, left hippocampal body, and right hippocampal tail. Faces (blue) activated bilateral hippocampal head and tail. Nature scenes (green) activated left hippocampal head, bilateral hippocampal body and bilateral hippocampal tail.

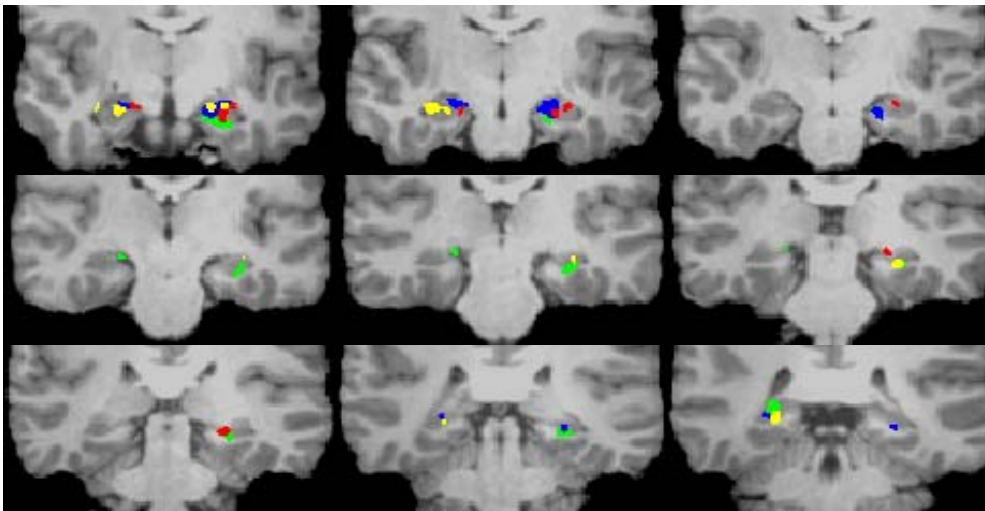


FIGURE: Areas of activation for each of the four types of material, overlaid on a representative subject's brain anatomy in Talairach space. The coronal images progress from anterior-to-posterior and show the head (1st row), body (2nd row) and tail (3rd row) of the hippocampus. All areas of activation are at least $p < 0.02$. Left Hemisphere is on the right and vice-versa.

Words-RED, Objects-YELLOW, Faces-BLUE, Nature Scenes-GREEN.

Discussion: The scanning resolution used in this study (1.56 mm X 1.56 mm X 2 mm) is higher than is typically reported for high-resolution fMRI studies of the MTL. Consistent with prior literature suggesting the advantages of small voxel size in cortical specificity of BOLD fMRI,[10] we were able to differentiate material-specific learning from basic visual processing

effects during a memory paradigm. Our high-resolution scanning methods allow detection and resolution of specific regions of activation within the hippocampus, showing specialization of different structures (i.e., head, body and tail) and each hemisphere related to encoding of different material types. We conclude that high-resolution limited-coverage acquisitions prove particularly useful in the study of parcellation of memory processes within the hippocampus.

Acknowledgements: This study was supported by the DOD grant no. DAMD 17-01-1-0741 from the U.S. Army Medical Research and Materiel Command and VA IDIQ contract number VA549-P-0027 awarded and administered by the Dallas, TX VA Medical Center. The content of this paper does not necessarily reflect the position or the policy of the U.S. government, and no official endorsement should be inferred.

References:

1. Ringe WK, Gopinath K, Cheshkov S, Sarkar S, Briggs R, Haley R. *Proc. Intl. Soc. Mag. Res. Med.* 2007; 15:193
2. Haxby JV, Gobbini MI, Furey ML, Ishai A, Schouten JL, Pietrini P. *Science* 2001; 293 (5539):2425-2430
3. Ishai A, Ungerleider LG, Martin A, Schouten JL, Haxby JV. *Proc.Natl.Acad.Sci.U.S.A* 1999; 96 (16):9379-9384
4. Ishai A, Ungerleider LG, Martin A, Haxby JV. *J.Cogn Neurosci.* 2000; 12 Suppl 2:35-51
5. Reber PJ, Wong EC, Buxton RB. *Hippocampus* 2002; 12 (3):363-376
6. Powell HW, Koeppe MJ, Symms MR, Boulby PA, Salek-Haddadi A, Thompson PJ, Duncan JS, Richardson MP. *Neuroimage.* 2005; 27 (1):231-239
7. Greicius MD, Krasnow B, Boyett-Anderson JM, Eliez S, Schatzberg AF, Reiss AL, Menon V. *Hippocampus* 2003; 13 (1):164-174
8. Golby AJ, Poldrack RA, Brewer JB, Spencer D, Desmond JE, Aron AP, Gabrieli JD. *Brain* 2001; 124 (Pt 9):1841-1854
9. Josephs O, Henson RN. *Philosophical Transactions of the Royal Society of London.Series B, Biological Sciences.* 1999; 354 (1387):1215-1228
10. Hyde JS, Biswal B.B., Jesmanowicz A. *Magnetic Resonance in Medicine* 2001; 46 (1):114-125