

MRI-guided focused ultrasound-enhanced chemotherapy of 9L rat gliosarcoma: Survival study

L. H. Treat^{1,2}, Y. Zhang¹, N. McDannold¹, and K. Hynynen^{1,3}

¹Radiology, Harvard Medical School and Brigham and Women's Hospital, Boston, MA, United States, ²Harvard-MIT Health Sciences and Technology, Cambridge, MA, United States, ³Sunnybrook Health Sciences Centre, Toronto, ON, Canada

Introduction

The selective permeability of the blood-brain barrier (BBB) remains a formidable obstacle in the use of chemotherapy to treat brain tumors. Using MRI-guided focused ultrasound with preformed microbubbles to locally disrupt the BBB and systemic administration of liposomal doxorubicin (DOX), we have previously confirmed that DOX could be delivered across the BBB at therapeutic levels in healthy rats [1]. In this study, we have examined the impact of such a treatment on survival in an *in vivo* rodent model of glioma.

Methods

Twenty-one male Sprague-Dawley rats (~0.3 kg) were anesthetized and the hair covering the skull removed. Each rat was implanted with $(0.5 - 1) \times 10^5$ 9L gliosarcoma cells at a depth of 3.5 mm from the dorsal surface of the brain through a burr hole drilled 2 mm lateral to the bregma. Eight days after implantation, each rat was treated either with MRI-guided focused ultrasound and intravenous injections of liposomal doxorubicin (FUS+DOX) or with intravenous liposomal doxorubicin alone (DOX only). For the ultrasound-enhanced (FUS+DOX) treatment (N = 12), the rat was laid on the MR table in a standard 3-Tesla scanner so that its skull was acoustically coupled with degassed water and exposed to ultrasound from a single-element focused transducer (diameter = 10 cm; radius of curvature = 8 cm; frequency = 1.7 MHz) mounted on a positioning device. T2-weighted and contrast-enhanced (Magnevist; Berlex Laboratories, Wayne, NJ; dose = 0.25 mL/kg) T1-weighted MR images of the brain were obtained to determine the size and location of the tumor. Sonications were pulsed (burst length 10 ms, pulse repetition frequency 1 Hz, duration 60–120 s) at 1-mm spacing targeted in and around the tumor. At the start of each sonication, a bolus of microbubble-based ultrasound contrast agent (Definity; Bristol-Myers Squibb, New York, NY) was injected simultaneously into the catheterized tail vein, followed immediately by doxorubicin (Doxil; Ortho Biotech, Bridgewater, NJ; total dose = 5.67 mg/kg) and flushed with 0.2 mL normal saline. Post-treatment contrast-enhanced T1-weighted MR images were obtained to confirm targeting of ultrasound-induced BBB disruption. For the rats treated with DOX only (N = 9), doxorubicin (total dose = 5.67 mg/kg) was injected into the catheterized tail vein at regular intervals following the sonication schedule, followed by 0.2 mL normal saline to flush the catheter. Rats were survived up to 55 days after implantation; their date of death (or euthanasia to limit suffering in the end-stages of cancer) was recorded.

Results

Contrast-enhanced imaging before and after sonication confirmed BBB disruption in regions surrounding the tumor (Fig. 1). Figure 2 shows the Kaplan-Meier estimate [2] of survival in rats treated with FUS+DOX compared to those treated with DOX only. The FUS+DOX group had a mean survival time (MST \pm SD) of 34.7 ± 10.3 days while the MST \pm SD of the DOX only group was 26.1 ± 3.4 days, representing an increase of approximately 33% in the group who received ultrasound-enhanced chemotherapy. The tumor in one animal in the DOX only group was no longer visible on follow-up MRI; this animal is considered lost to follow-up (censored) after Day 28. The Log-Rank test for the statistical difference of these two curves gives $\chi^2 = 3.97$ ($0.02 < p < 0.05$).

Discussion

We have previously demonstrated that MRI-guided focused ultrasound can effectively deliver a therapeutic dose of doxorubicin across the blood-brain barrier in normal brain [1]. Here, we have shown that targeted drug delivery by MRI-guided focused ultrasound significantly improves survival time in rats with aggressive glioma, compared to chemotherapy alone. Such demonstrated efficacy in an *in vivo* tumor model represents a large step forward in the development of this technique toward treating patients with disorders of the central nervous system.

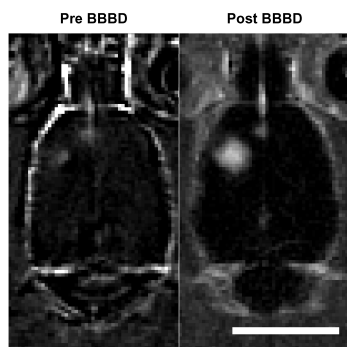
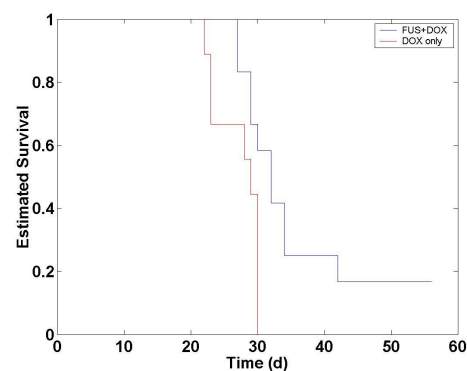


Figure 1 (left). Contrast-enhanced T1-weighted images of a horizontal slice of the rat brain, showing the tumor before and after treatment with focused ultrasound-induced BBB disruption and liposomal doxorubicin. Scale bar = 10 mm.

Figure 2 (right). Kaplan-Meier estimate showing increased mean survival time in rats treated with MRI-guided focused ultrasound and doxorubicin (N = 12), compared to rats treated with doxorubicin alone (N = 9) ($\chi^2 = 3.97$; $0.02 < p < 0.05$).



References

1. Treat LH, McDannold N, Vykhodtseva N, Zhang Y, Tam K, Hynynen K. *Int J Cancer* 2007;121:901-907.
2. Kaplan EL, Meier P. *J Am Stat Assoc* 1958;53:457-481.