

Methodology for rapid Cardiac Axis generation from non gated cardiac MR images

S. Dwivedi¹, V. Vaidya¹, R. Mullick¹, T. Foo², and V. Ho³

¹Imaging Technologies, GE Global Research, Bangalore, Karnataka, India, ²Imaging Technologies, GE Global Research, Niskayuna, NY, United States, ³National Naval Medical Center, Bethesda, MD, United States

Introduction: Cardiac Magnetic Resonance Imaging (MRI) is an excellent tool in analysis of left ventricular (LV) functioning[3]. Short axis cardiac MR images are most suitable to study the LV function [4], but preparation for generating these images is time consuming and requires sound understanding of the cardiac anatomy. Accurate and reproducible determination of short axis to study the LV function over time is challenging and time consuming for medical technician and radiologists alike. Prior effort [1] by Lelieveldt et al has involved using digital atlas matching of thorax to localizer images, which resulted in generating the location and the axis of the left ventricle. An average variation of 9.7 degrees has been reported. Jackson et al [2] have acquired the localizer images using a mean short axis orientation followed by blood pool segmentation and generate the short axis. The second study has reported a variation of 12 degrees from ground truth (GT) on breath held localizer scans. We have worked on 5 clinical datasets (non-gated axial fiesta localizer) from NNMCC (National Navy Medical College) Bethesda, scanned on the GE 1.5 Signa Excite scanner. We have used an anatomy guided approach intermixed with imaging techniques to locate the 3D orientation (azimuth and elevation angle) of the left ventricle and thereby generating the cardiac axis. The mean deviation from the prescribed short-axis at the clinical site (ground truth) using our approach was 5.6 degrees.

Methods: *Acquisition:* MR - Five patients were scanned on a 1.5T Signa Excite MRI scanner (GE Healthcare, Waukesha, WI) under IRB approved protocols after obtaining informed consent. Non gated FIESTA Images: TR: 3.033ms; TE: 1.308ms; Spacing between slices: 8mm, Bandwidth: 125Khz, Matrix: 256 x 256, NEX: 1, FoV: 35x35 cm.

Processing: The core challenges in locating the left ventricle were: 1) Datasets being free breathing, there was no consistency in the shape of left ventricle images across the slices due to motion 2) Number of slices with left ventricle images were few as the spacing between slices was 8mm; 3) Low resolution images. In order to overcome these broad challenges, the approach begins with applying advanced imaging operations followed by anatomically driven heuristics to generate the approximate elliptical axis of the left ventricle per 2D slice. Average azimuthal orientation of the left ventricle is generated from the axis in the previous step. Azimuthal angle is used to generate the mid ventricular long axis view(MVLAV) of the axial volume mimicing and facilitating the routine clinical process. From this volume, we interpret the elevation angle of the left ventricle using image processing methods along with the anatomical priors. The short axis is generated using the azimuthal and elevation angle by standard transformations of spherical coordinate system. Figure 1 below shows the basic methodology of short axis generation. Figure 2 shows the pipeline for elevation angle determination and Figure 3 shows the pipeline for azimuth angle determination.

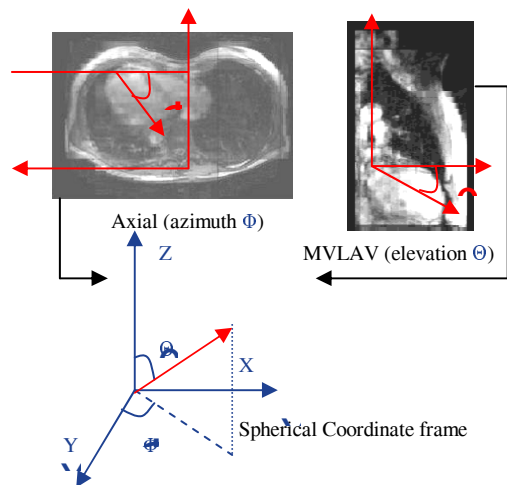


Figure 1: Basic Approach for Left ventricle axis determination (X, Y, Z)

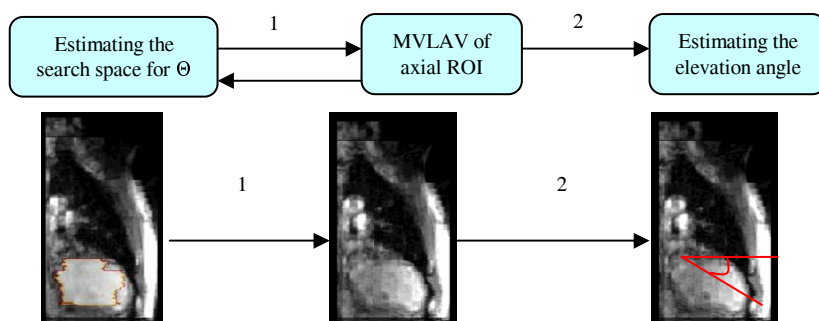


Figure 2: Pipeline for elevation angle estimation.

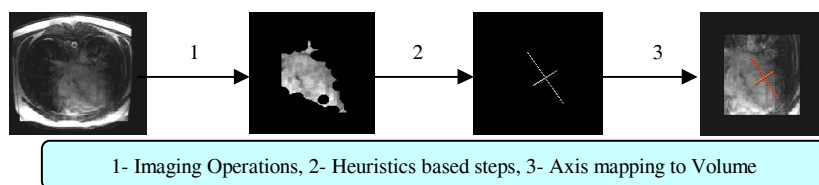


Figure 3: Pipeline for azimuth angle estimation

Case ID: (Age, Weight) -> 6065: (60,63.5), 7173: (48,74.8), 7886: (44,113.4), 8014: (27,72.6), 8259: (49,79.4)

Case	Axis Calculated	Axis GT	Error
6065	(0.679,-0.547, -0.490)	(0.736,-0.515, -0.439)	4.75
7173	(0.612,-0.660, -0.436)	(0.643,-0.639, -0.422)	2.22
7886	(0.606,-0.641, -0.390)	(0.636,-0.700, -0.198)	19.67
8014	(0.649,-0.653, -0.391)	(0.583,-0.676, -0.451)	5.04
8259	(0.623,-0.604, -0.498)	(0.533,-0.738, -0.413)	10.43
Average Variation			5.61

Table showing calculated and ground truth (GT) short axis and the variation from GT

Results: Five patient (all male, age and weight shown above) datasets were used to validate the approach used. Average variation in the azimuthal angle from GT is 3.62° and average variation in elevation angle from GT is 4.21°. The short axis generated from the azimuth and elevation shows an average variation of 5.61° (measures as the solid angle between axes) from GT. The clinical cases considered are shown in the table towards left, where the computed and GT short axis are compared. The error reported in the table is the solid angle between the two 3D vectors. Case 7886 may have a different acquisition protocol as a tilt is observed on closer analysis of the GT short axis views and GT verification is in process. Four additional patient datasets are acquired as part of prospective study and results are expected shortly. Average time taken per dataset is 120 seconds approximately.

References:

- 1- Lelieveldt BPF, van der Geest RJ, Lamb HJ, Kayser HWM, Reiber JHC. Automated observer-independent acquisition of cardiac short-axis MR images: a pilot study. Radiology 2001; 221(2): 537-42
- 2- Clare E. Jackson, Matthew D. Robson, Jane M. Francis, J. Alison Noble, Computerised planning of the acquisition of cardiac MR images, Computerized Medical Imaging and Graphics, Volume 28, Issue 7, Pages 411-418
- 3- Yang PC, Kerr AB, Liu AC, et al. New real-time interactive cardiac magnetic resonance imaging system complements echocardiography. Journal of American College of Cardiology 1998; 32:2049-2056.
- 4- Haag UJ, Maier SE, Jakob M, et al. Left ventricular wall thickness measurements by magnetic resonance: a validation study. International Journal Cardiac Imaging 1991; 7:31-4