

In-Vivo evaluation of cartilage repair using Steady-State Diffusion Weighted Imaging

T. C. Mamisch¹, M. I. Menzel², G. H. Welsch³, B. Bittersohl⁴, P. Szomolanyi³, S. Marlovits⁵, and S. Trattnig³

¹Orthopaedic Surgery, University Bern, Bern, Switzerland, ²Research Centre Juelich, Germany, ³MR Centre, University Vienna, Austria, ⁴Department of Orthopaedic Surgery, University Bern, Switzerland, ⁵Trauma Surgery, University Vienna, Austria

Introduction

Various MR imaging sequences have given proof of their ability to visualize ultra structural components and to reveal the biochemical composition of cartilage. One encouraging approach in the means of cartilage grading is the use of diffusion weighted sequences [1,2]. Conventional DWI based on spin-echo (SE) sequences is relatively insensitive to susceptibility effects, but diffusion weighted SE sequences require a long acquisition time, which, for practical reasons, in a clinical examination is inapplicable. Alternatively diffusion imaging can be based on steady state free precession sequences (SSFP) which realize a diffusion weighting in relatively short echo times [3]. Aims of this study are to use a three-dimensional steady state diffusion technique, called PSIF (which is a time reversed FISP (Fast Imaging by Steady State Precession) sequence in a cross-sectional study of patients after cartilage repair (matrix-associated autologous chondrocyte transplantation (MACT)) to assess

1. Feasibility for diffusion-weighted imaging of cartilage and cartilage transplants in a clinical study
2. Follow up of cartilage transplant maturation in patients after cartilage repair.

Material and Method

15 patients after different time points of matrix-associated autologous chondrocyte transplantation of the knee joint underwent MR scanning at a 3Tesla scanner. The group was subdivided into four groups based on the postoperative time intervals: Group 1: 3 and 6 months after surgery (3 patients); Group 2: 10 – 13 months (3 patients); Group 3: 19 – 22 months (5 patients); Group 4: 26 – 42 months (4 patients). The imaging protocol included a three-dimensional Double Echo Steady-State (3D-DESS) for morphological evaluation and a three-dimensional balanced steady-state gradient echo pulse sequence with diffusion weighting (3D-DW PSIF). In order to allow a semi-quantitative assessment of the diffusional behaviour in the cartilage, the diffusion sequence protocol consisted of 2 separate but immediately consecutive measurement using none (0), and $75 \text{ mT} \cdot \text{ms} \cdot \text{m}^{-1}$ monopolar diffusion gradient moments for DWI and otherwise identical imaging parameters. For later evaluation, the quotient image (non-diffusion weighted / diffusion-weighted image) was calculated using the build-in software routines of the clinical scanner. Imaging parameters of the DW-PSIF acquisition were as follows: (TR = 16.3ms, TE = 6.1ms, flip angle = 30° , 48 slices, $170 \times 170 \text{ mm}$ FoV, 256×256 matrix size). For the evaluation 12 region of interest based on anatomical position within the cartilage repair tissue and 3 of healthy appearing cartilage within the same knee joint were assessed and compared.

Results

The global diffusion quotient found in repair cartilage was significantly higher than diffusion values present in healthy cartilage. The mean global diffusion quotient of healthy reference cartilage of all 15 patients averaging over 45 ROIs was 1.19 ± 0.27 compared to the mean global diffusion quotient of repair tissue of 1.64 ± 0.62 in group 1, 1.36 ± 0.51 in group 2, 1.36 ± 0.50 in group 3, and 1.50 ± 0.86 in group 4. A comparison of repair and reference cartilage statistically showed high significant difference ($p < 0.01$) in group 1, and significant differences ($p < 0.05$) in the groups 2 to 4. (Fig.1). By comparison of different anatomical location within the transplant from anterior to posterior statistically significant difference between diffusion quotients in reference and repair cartilage in all 3 aspects could only be found in group 1 (anterior: $p < 0.01$, central: $p = 0.02$, posterior: $p = 0.035$). With regard to the groups 2 – 4, the anterior aspect of the graft, only, revealed significant difference compared to the reference tissue (group 2: $p = 0.031$; group 3: $p = 0.012$; group 4: $p = 0.002$). In case of the posterior aspect, no statistically significant differences were found ($p > 0.05$). The standard deviation in repair cartilage was significantly higher compared to the reference cartilage representing an increased heterogeneity of cartilage repair tissue. The maturation process could be shown by changes in heterogeneity and decrease of the diffusion quotient differences to the surrounding cartilage (Fig.2).

Discussion

With this study we demonstrated the feasibility of diffusion-weighted PSIF imaging in vivo for assessment of cartilage repair tissue with high resolution protocol. The results show that in the follow up at different time points after MACT the diffusion behaviour of the transplants is changing. Our preliminary results show that follow up studies of maturation of cartilage transplant patients may provide additional information in comparison to morphological assessment. With imaging techniques as DW-PSIF and a semi-quantitative evaluation forming the quotient and thus eliminating the influence of T_1 and T_2 as presented here, functional analysis of cartilage and cartilage repair with high SNR and resolution can be achieved within comparably short acquisition times.

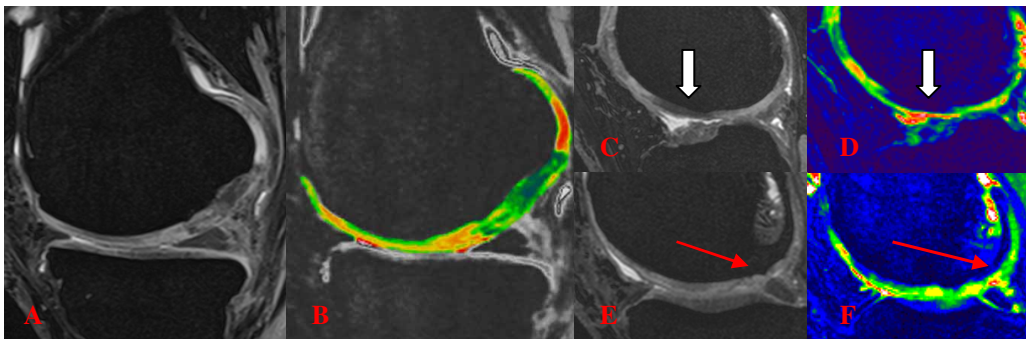


Fig1: 3D –DESS image and color-coded diffusion quotient of Cartilage repair after 22month showing changes to the surrounding cartilage and heterogeneity. (A+B). Upper Images (C+D) showing Cartilage repair after 6 month with high significant differences (white arrow). Lower images (E+F) showing cartilage repair tissue after 42 month with adaptation of the cartilage repair tissue to the surrounding tissue (red arrows)

References

1. Miller KL, Hargreaves BA, Gold GE, Pauly JM. Steady-state diffusion-weighted imaging of in vivo knee cartilage. Magn Reson Med. 2004 Feb;51(2):394-8.
2. Recht MP, Goodwin DW, Winalski CS, White LM. MRI of articular cartilage: revisiting current status and future directions. AJR Am J Roentgenol. 2005 Oct;185(4):899-914. Review.
3. Deoni SC, Peters TM, Rutt BK. Quantitative diffusion imaging with steady-state free precession. Magn Reson Med. 2004 Feb;51(2):428-33.

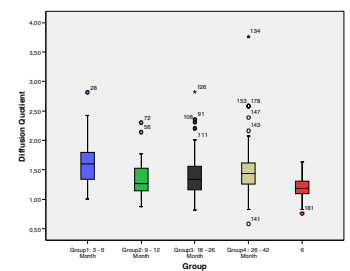


Fig.2: Diffusion Quotient in the Different groups compared to the reference cartilage. Slight adaptation of the values over time with statistical differences within all groups.