

Optimized “all-in-one” liver MRI featuring Gd-EOB-DTPA administration in the evaluation of potential living liver donors: Preliminary results of a comparison with “all-in-one” contrast-enhanced multislice-CT

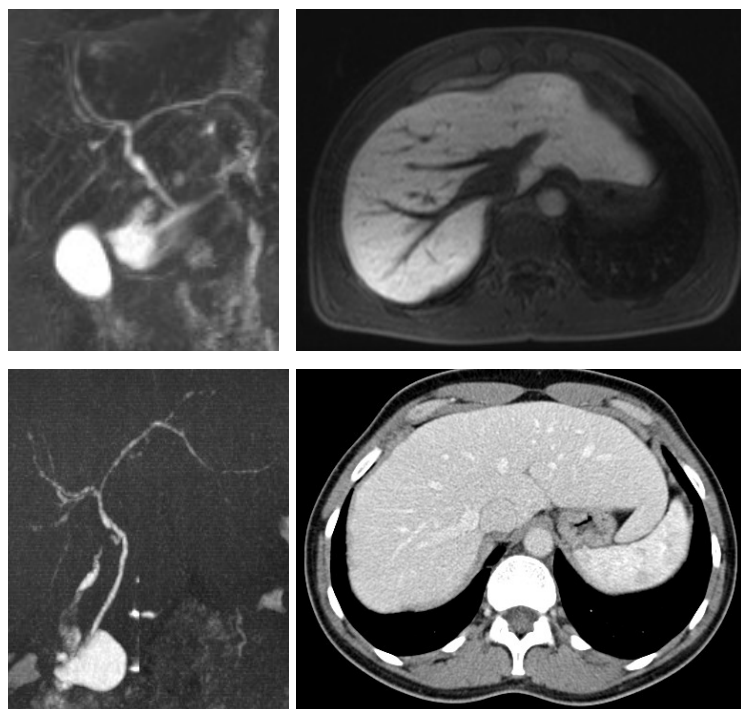
S. Kinner¹, S. C. Ladd¹, J. Barkhausen¹, C. Valentin-Gamazo², S. Lunkeit¹, S. Maderwald¹, A. Radtke², and T. Schröder¹

¹Department of Diagnostic and Interventional Radiology and Neuroradiology, University Hospital Essen, Essen, NRW, Germany, ²Department of Transplantation Surgery, University Hospital Essen, Essen, NRW, Germany

Introduction: Living donor liver transplantation (LDLT) has evolved into a frequently considered therapeutic option. Reliable assessment of the hepatic parenchymal morphology and the transplant volumes, as well as a detailed analysis of the biliary and vascular anatomy is needed to reduce the rate of complications in these otherwise healthy donors. To reduce the diagnostic procedural efforts in the pre-harvest evaluation to a minimum, comprehensive “all-in-one” magnetic resonance imaging (MRI)- and computed tomography (CT) protocols have been advocated [1-3]. Due to notable improvements in the recent years, MRI provides high temporal and spatial resolution for liver imaging, rendering a distinct delineation of the vascular and parenchymal anatomy. Furthermore, liver-specific contrast agents like Gd-EOB-DTPA are available, which do not only facilitate vascular assessment but are also excreted into the biliary tree and therefore permit biliary anatomy assessment to a better extent than heavily T2w MR cholangiographies. Aim of this study was to compare an all-in-one MR protocol including administration of Gd-EOB-DTPA with contrast-enhanced multi-detector row CT (ceMDCT).

Materials and Methods: MRI and ceMDCT was performed in 10 consecutive potential living donors of the right hepatic lobe (mean age 32 years). The MR scan protocol (Magnetom Avanto, Siemens, Germany) included automated i.v. administration of Gd-EOB-DTPA (Primovist[®], Schering, Germany). The following sequences were acquired before contrast administration: axial T1-weighted 2D spoiled-gradient echo (FLASH), coronal T2-weighted True Fast Imaging With Steady Precession (TrueFISP), axial T2-weighted 2D Half-Fourier acquisition single-shot turbo spin-echo (HASTE) including spectro-spatial fat saturation, coronal HASTE and coronal T2-weighted turbo-spin echo for MRCP. Then contrast-enhanced axial dynamic 3D FLASH was added. For this purpose, arterial imaging was performed after individual test bolus timing, and after intermittent 30-second delays portal and hepatic venous imaging was performed. Finally, a delayed post-contrast axial T1-weighted 2D FLASH including fat saturation was acquired. After a delay of 1 hour patients were examined again with a T1-weighted 3D FLASH sequence with inversion recovery pulse to analyze the biliary system after excretion of the contrast agent. CT Imaging was performed on a 16-row Multidetector CT scanner (Sensation16[®], Siemens, Germany). To delineate the biliary system, the first CT-image set was acquired 45min following infusion of 100 ml of a biliary contrast agent (Biliscopin[®], Schering, Germany). Subsequently, CT angiography (CTA) was performed for display of the arterial hepatic and of the portal and hepatic venous anatomy, following automated injection of 140 ml of an iodinated contrast agent (Ultravist300[®], Schering, Germany). All three scans used the same imaging parameters (kVp 120, mAs 150-180, slice width/collimation 5/0.75 mm, and reconstruction 1 mm slice thickness). Analyses both from MRI and ceMDCT image data were based on source images as well as on post processed images (workstation: syngo[®], Siemens, Germany). Two experienced radiologists analysed the images focusing on the following aspects:

- morphology of the biliary, arterial, hepatic venous and portal venous system and detection of anatomic variants
 - exclusion of focal lesions in the liver and the surrounding organs
- Image quality was rated on a 4-point scale (IQR): 4-excellent; 3-good; 2-sufficient; 1-non-diagnostic image quality.



Results: According to the Michels classification, MRI revealed 3 anatomical arterial variants (IQR mean 2.5), while CTA showed 5 variants (IQR mean 3.5). According to Couinaud-Classification, MRI revealed 1 biliary variant (IQR mean 2.0) as did ceMDCT (IQR mean 3.2). MRI and ceMDCT imaging of the hepatic and portal veins each revealed 1 variant, (IQR mean 3.6 vs. 3.7). Both MRI and CT detected one benign parenchymal lesion (haemangioma), but the overall IQRs differed between 3.8 for MRI and 3.5 for CT.

Conclusion: Recent technical improvements in combination with i.v. administration of Primovist, at the same time serving as vascular and biliary contrast agent, lead to sufficiently high spatial resolution if compared to CT. For evaluation of potential living liver donors, MRI shows nearly as good diagnostic performance as ceMDCT, providing all necessary preoperative data by one single diagnostic appointment. Reflecting the lack of radiation exposure, MRI should be the preferred exam for – the predominantly young - liver donors in the future, but certainly should be evaluated in a larger patient group.

Figure 1:

Left side: Corresponding biliary images: MR (top, coronal T2w TSE 3D restore), CT (bottom, 3D reconstruction) showing a trifurcation at the upper hepatic biliary confluent.

Right side: Corresponding venous images (MR top, CT bottom). Note that the veins were evaluated “inverse” due to the high contrast deriving from bright signal of the liver and low signal of the veins.

References

1. Lee VS, Morgan GR, Teperman, LW, et al.: MR imaging as the sole preoperative imaging modality for right hepatectomy: a prospective study of living adult-to-adult liver donor candidates. *AJR Am J Roentgenol* 2001; 176(6): 1475-82
2. Kamel IR, Kruskal JB, Pomfret EA, et al.: Impact of multidetector CT on donor selection and surgical planning before living adult right lobe liver transplantation. *AJR Am J Roentgenol* 2001; 176(1): 193-200
3. Schroeder T, Malago M, Debatin JF, et al.: "All-in-one" imaging protocols for the evaluation of potential living liver donors: comparison of magnetic resonance imaging and multidetector computed tomography. *Liver Transpl.* 2005 Jul;11(7):776-87.