

Non-contrast-enhanced MR angiography of the thoracic aorta using a whole-chest 3D steady-state with free-precession technique

C. J-P. François¹, V. Deshpande², R. Jerecic², P. Weale², J. C. Carr¹, and K. Dill¹

¹Department of Radiology, Northwestern University, Chicago, IL, United States, ²MR Research and Development, Siemens Medical Solutions USA, Inc., Malvern, PA, United States

Introduction:

Magnetic resonance angiography (MRA) is a valuable method of evaluating the thoracic aorta in a variety of clinical situations, including assessing patients with aneurysms, pseudoaneurysms, intramural hematomas, penetrating ulcerative plaques, dissections, stenoses, or congenital anomalies. Various MR techniques have been validated to assess the size and morphology of the aorta.^{1,2} Current MRA protocols rely on contrast material enhanced sequences to image the aorta. For patients with difficult intravenous access, renal insufficiency or who are pregnant, non-contrast-enhanced MRA techniques could be an alternative method to evaluate the vasculature. The purpose of this study is to assess the feasibility of a non-contrast technique for aortic MR angiography using a non-selective, segmented 3D steady-state with free precession technique (TrueFISP) with motion adaptive respiratory navigators.

Methods:

Clinical MRA studies were performed in 23 patients on a 1.5T scanner (MAGNETOM Avanto, Siemens, Erlangen, Germany) and were retrospectively reviewed. A contrast-enhanced ECG-gated high resolution 3D FLASH sequence (CEMRA), which provides artifact-free images of the entire aorta, was performed in each patient (TA: 23s, 0.8mm x 1.3mm s 1.5 mm resolution). A non-contrast-enhanced, 3D TrueFISP sequence was also performed through the entire chest (400mm FOV) with a non-selective excitation pulse (1.6mm x 1.6mm x 1.5mm resolution). The non-selective approach is used to reduce TR with consequent reduction in image artifacts related to off-resonance effects. A motion adaptive navigator echo scheme was used to optimize scan efficiency in cases where drift of the end-expiratory diaphragm position extends scan duration. Qualitative analysis was performed by two reviewers. Images were evaluated for conspicuity of the aortic root, ascending aorta, aortic arch and descending aorta (0 = poor; 1 = adequate; 2 = good; 3 = excellent). The presence or absence of pathology was noted. Quantitative analysis was performed on a computer workstation (syngo MMWP, Siemens, Erlangen, Germany). Orthogonal transaxial measurements of the thoracic aorta were made at the annulus, sinuses of Vasalva, sinotubular junction, mid ascending aorta at its greatest diameter, arch proximal to innominate artery, arch distal to left subclavian artery, and descending thoracic aorta at hiatus. The correlation coefficient and the mean difference between the diameters measured using CEMRA images and 3D TrueFISP images were determined.

Results:

The average age of the patients was 41.3 years +/- 19.8. All studies were considered diagnostic, for both CE-MRA and segmented 3D TrueFISP. The average image acquisition time for the 3D TrueFISP sequence was 9.3 minutes +/- 4.3 minutes. The average conspicuity of the aortic root for the CEMRA studies was 2.3 +/- 0.8 and for the 3D TrueFISP studies was 2.8 +/- 0.4 (p-value = 0.012). Conspicuity scores were not significantly different for other anatomic locations. All pathology was equally detected for both techniques. The measurements made from the 3D TrueFISP images correlated very closely, $r = 0.98$, with those made with CEMRA. The mean difference between diameters determined from the 3D TrueFISP images and the CEMRA images was -0.04 ± 0.17 cm.

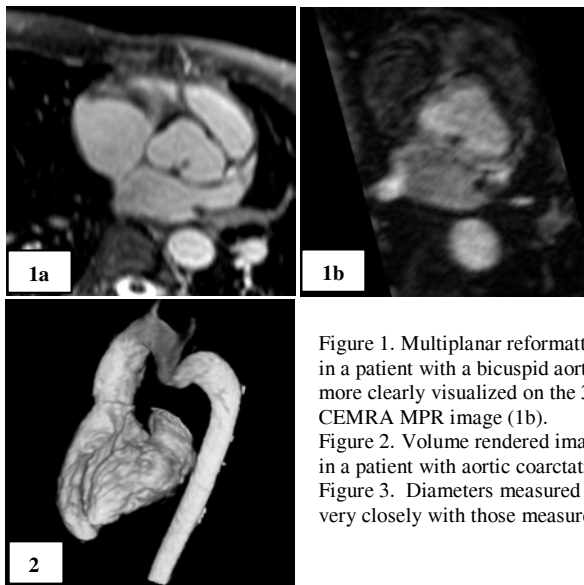
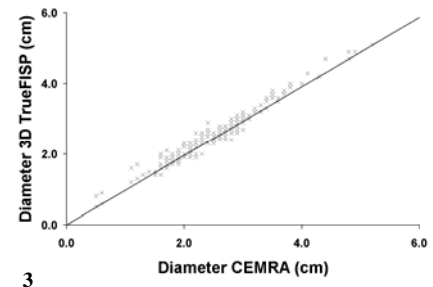


Figure 1. Multiplanar reformatted (MPR) image of the sinuses of Vasalva in a patient with a bicuspid aortic valve. The wall of the aortic root is more clearly visualized on the 3D TrueFISP MPR image (1a) than on the CEMRA MPR image (1b).
Figure 2. Volume rendered image generated from a 3D TrueFISP data-set in a patient with aortic coarctation.
Figure 3. Diameters measured from the 3D TrueFISP data-sets correlate very closely with those measured from the CEMRA data-sets ($r = 0.98$).

Conclusions:

The novel, 3D TrueFISP approach evaluated in this study permits imaging of the whole thorax with good image contrast maintained throughout the heart and thoracic vasculature. 3D TrueFISP MRA of the thoracic aorta was of higher overall quality than CEMRA with measurements that very closely correlated with those determined with CEMRA. Even though the 3D TrueFISP images take longer to acquire, this technique could be a valuable alternative in patients with difficult intravenous access, renal insufficiency or who are pregnant. In addition, the 3D TrueFISP images provided better visualization of the aortic root and extra-luminal anatomy, especially the aortic wall, which may be useful in conditions such as vasculitis or intramural hematoma which are not seen with CEMRA.



References:

1. Carr JC, Finn JP. MR imaging of the thoracic aorta. *Magn Reson Imaging Clin N Am* 2003; 11: 135-148.
2. Russo V, Renzulli M, Buttazzi K, Fattori R. Acquired diseases of the thoracic aorta: role of MRI and MRA. *Eur Radiol* 2006; 16: 852-865.