

FAST REGISTRATION FOR MOTION CORRECTION OF BREAST MR IMAGES

J. Buurman¹, U. Kose¹, and F. A. Gerritsen¹

¹Healthcare Informatics, Philips Medical Systems, Best, Netherlands

Problem

A typical MR examination of the breast includes a dynamic contrast-enhanced scan of both breasts. As part of their analysis, the temporal behavior of suspicious areas is examined where the combination of rapid enhancement and subsequent washout is correlated with malignancy [Kuhl et al., 1999]. Patient motion during the scan may cause a misinterpretation of this behavior, when a certain position in an image corresponds to enhancing tissue at one time and to non-enhancing tissue in another. Registration of the dynamic scan may alleviate this problem. However, published methods [e.g. Denton et al. 1999, Renisch et al. 2006, Schnabel et al. 2003] are presently too time-consuming for computation during the diagnostic session, so that motion correction must be computed beforehand. This problem is likely to remain, since although the speed of computers increases, the size of the data does too.

Methods

We present a motion correction method that is sufficiently fast for computation during a diagnostic session. By this, we mean that the results should typically be available in less than one minute. This is obtained by combining (a) detection of the breasts as regions of interest [Koenig et al. 2005], (b) affine registration per region as a good approximation of the actual motion [Sivaramakrishna 2004], and (c) recursive registration (each time instance D_i is compared to the previous one, see fig.1) to further speed up the process. Subtracted and/or non-subtracted images (as well as color overlays and Maximum Intensity Projections - MIPs) are presented to the user, who can choose interactively between no registration, registration on the right breast and registration on the left breast. In all cases, full images are presented to the user in order not to preclude findings outside of the breast itself (e.g. in the axilla), see fig. 2.

There have been various attempts to quantify the effect of motion correction. Since we have observed that the effect of motion correction is most noticeable as the removal of artifacts in MIPs, we have computed the relative change of signal in a MIP after subtraction, C :

$$C = 100 - \frac{I_{reg}}{I_{unreg}} \cdot 100\%$$

where I_{reg} and I_{unreg} are the sums of the grey values of a MIP of the region of interest registered and unregistered, respectively. While this number itself is influenced by both the dataset and the algorithm, it does allow a meaningful comparison of algorithms on the same datasets.

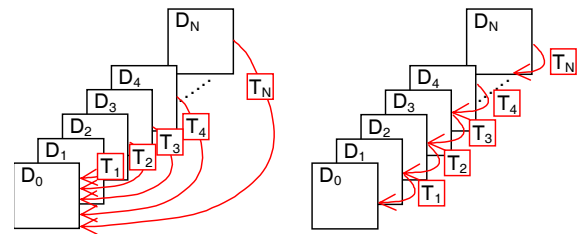


Fig. 1. Left: direct registration, right: recursive registration.

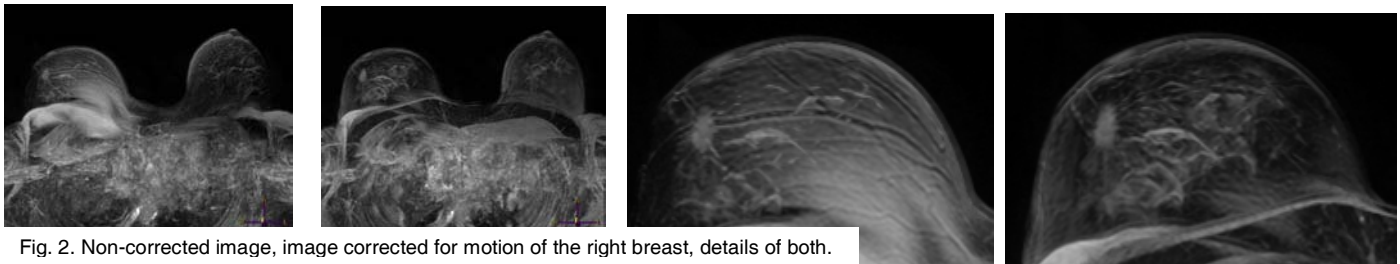


Fig. 2. Non-corrected image, image corrected for motion of the right breast, details of both.

Results

We have applied the motion correction method to a series of 20 clinical scans from several sites and scanners. On average, one time instance was registered to another in 5.1 s. By doing this registration in parallel with other processing, it can be done without noticeable delay for the user. Recursive registration resulted in a speedup of 28%. Fig. 3 shows a histogram of the relative signal change C for these cases, for both recursive and direct registration. It demonstrates a large spread in the improvement made by registration (0-59%, average 18%), in agreement with the observation that visibly, the motion artifacts range from none to severe. Qualitatively, recursive and direct registration performed approximately equally well. The system is currently under clinical evaluation.

Conclusions

We have presented an approach to motion correction for DCE-MRI of the breast that is sufficiently fast for computation during a diagnostic session. The speed was realized by computing an affine registration of regions of interest only. A speedup of 28% was realized by computing the registration in a recursive manner.

References

- Kuhl C.K. et al., Dynamic Breast MR Imaging: Are Signal Intensity Time Course Data Useful for Differential Diagnosis of Enhancing Lesions?, *Radiology*. 1999;211:101-110.
- Denton E. et al. Comparison and evaluation of rigid and non-rigid registration of breast MR images, *Proc of SPIE* Vol 3661, 1999, 78-87.
- Renisch S. et al., Dedicated registration for DCE MRI mammography, *Proc. of SPIE* Vol 6144, 2006.
- Schnabel et al., Validation of Non-Rigid Image Registration using Finite Element Methods: Application to Breast MR Images. *IEEE Trans. Med. Imaging* 22(2): 238-247 (2003).
- Koenig M. et al., Automatic cropping of breast regions for registration in MR mammography, *Proc. of SPIE* Vol. 5747, 2005, 1563-1570.
- Sivaramakrishna R., 3D Breast Image Registration – A Review, *Technology in Cancer Research & Treatment*, Volume 4, Number 1, February (2005).

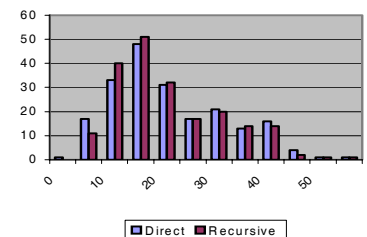


Fig. 3. Histogram of relative signal change C .